

The Use of the Operating Microscope in Endodontics

Gary B. Carr and Arnaldo Castellucci

INTRODUCTION

Endodontists have frequently boasted they can do much of their work blindfolded simply because there is “nothing to see.” The truth of the matter is that there is a great deal to see if only we had the right tools.¹

In the last fifteen years for both non-surgical and surgical endodontics, there has been an explosion of new technologies, new instruments and new materials. These developments have improved the precision with which endodontics can be performed. These advances have enabled clinicians to complete procedures which were once considered impossible or which could be performed only by extremely talented or lucky clinicians. The most important revolution has been the introduction and then the widespread adoption of the operating microscope.

Operating microscopes have been used for decades in many other medical disciplines: ophthalmology, neurosurgery, reconstructive surgery, otorhinolaryngology, and vascular surgery. Its introduction into dentistry in the last fifteen years, particularly in endodontics, has revolutionized how endodontics is practiced worldwide.

ON THE RELATIVE SIZES OF THINGS

It is difficult, even for a scientist, to have an intuitive understanding of size. Specifically, a dentist must have an accurate understanding of the relationship between the gross dimensions involved in restorative procedures and the

Until recently, endodontic therapy was performed using our tactile sensitivity, and the only way to “see” inside the root canal system was to take a radiograph. To perform endodontic therapy entailed “working blind,” in that most of the effort was done using only tactile skills with a minimum of visual information available. Before the introduction of the operating microscope we could “feel” the presence of a problem (a ledge, a perforation, a blockage, a broken instrument), and the clinical management of that problem was never predictable and depended on happenstance. Most endodontic procedures occurred in a visual void which placed a premium on the doctor’s tactile dexterity, mental imaging and perseverance.

The introduction of the operating microscope has changed both non-surgical and surgical endodontics. In non-surgical endodontics, every challenge existing in the straight portion of the root canal system, even if located in the most apical part, can be easily seen and managed competently under the microscope. In surgical endodontics, it is possible to carefully examine the apical segment of the root-end and perform an apical resection of the root without an exaggerated bevel, thereby making Class I cavity preparations along the longitudinal axis of the root easy to perform.

The purpose of this chapter is to provide the basic information of how an operating microscope is used in a clinical endodontic practice and to give an overview of its clinical and surgical applications.

dimensions of those deleterious elements that cause restoration failure: bacteria, open margins, imperfection in restorative materials, etc. In other words, a filling or a crown may appear to be well placed, but if bacteria can



A

leak through the junction between tooth and restorative material, then treatment is compromised.

A brief review of relative size may be helpful. Cells are measured in microns (millionths of a meter) and a single bacterial cell is about one micron in diameter. One cubic inch of bacteria can hold about a billion cells. A typical human (eukaryotic) cell is 25 microns in diameter so that an average cell can hold more than 10,000 bacteria. By comparison, viruses are so small that thousands can fit

within a single bacterial cell. Simple calculations show that one cubic inch can contain millions of billions of viruses. Unfortunately, the calculations do not end there. For example, macromolecules (e.g., bacterial toxins, etc.) are measured in nanometers, or one billionth of a meter (Fig. 32.1). Some of these bacterial toxins are so potent that even nanogram quantities can cause serious complications and even death. Clearly, dentists are at a severe disadvantage in their attempts to replace natural tooth structure with artificial materials that do not leak, in view of the virtually invisible microbiologic threats to restoration integrity.⁵

THE LIMITS OF HUMAN VISION

Webster defines resolution as the ability of an optical system to make clear and distinguishable two separate entities. Although clinicians have routinely strived to create bacterial-free seals, the resolving power of the unaided human eye is only .2 mm. In other words, most people who view two points closer than .2 mm will see only one point. For example, Figure 32.2 shows an image of a dollar bill. The lines making up George Washington's face are .2mm apart. If one holds the bill close enough, one can probably just barely



make out the separation between these lines. In fact, if they were any closer together, you would not be able to discern

that they were separate lines. The square boxes behind Washington's head are .1 mm apart and are not discernable as separate boxes by most people. They are beyond the resolving power of the unaided human eye. For comparison sake, it would take about 100 bacteria to span that square. Clinically, most dental practitioners will not be able to see an open margin smaller than .2 mm. The film thickness of most crown and bridge cements is 25 microns (.025 mm), or well beyond the resolving power of the naked eye.

Optical aids (loupes, microscopes, surgical headlamps, fiber optic handpiece lights, etc.) can improve resolution by many orders of magnitude. For example, a common operating microscope can raise the resolving limit from .2 mm to .006 mm (6 microns), a dramatic improvement. Figure 32.3 shows the improvement in resolution obtained by the standard operating microscope used in dentistry today. At the highest power, a margin open only .006 mm is essentially sealed and even beyond the common cement thickness used in restorative dentistry. Table I summarizes the relationship between object size and resolving power.





Fig 32.2. A, 3x magnification B, 5x magnification C, 8x magnification D, 10x magnification E, 18x magnification. These are the five different magnifications of a dollar bill as seen through a Global 5-step microscope.

Table I

2.7x	4.1x	6.8x	10.9x	17x	80.9mm	53.9mm	32.4mm	0.2mm
								12.9mm

WHY ENHANCED VISION IS NECESSARY IN DENTISTRY

It should be obvious from the previous discussion that any device that enhances or improves a clinician's resolving power is extremely beneficial in producing precision

dentistry. Restorative dentists, periodontists, and endodontists routinely perform procedures requiring resolution well beyond the .2 mm limit of human sight. Crown margins, scaling procedures, incisions, root canal

location, caries removal, furcation and perforation repair, post placement or removal, and bone-and soft-tissue grafting procedures are only a few of the procedures that demand tolerances well beyond the .2 mm limit.

OPTICAL PRINCIPLES

Since all clinicians must “construct” three-dimensional structures in a patient’s mouth, stereopsis, or three-dimensional perception, is critical to achieving precision dentistry. Dentists appreciate that human mouth is a relatively small space in which to operate, especially considering the size of the available instruments (burs, handpieces, etc.) and the comparatively large size of the operator’s hands. Attempts have been made to use the magnifying endoscopes used in arthroscopic procedures but these devices require viewing on a two-dimensional monitor and the limitations of working in 2D space are too restrictive to be useful.

Several elements are important for consideration in improving clinical visualization. Included are factors such as:

Most people cannot refocus at distances closer than 10-12 cm. Furthermore, as the eye-subject distance (i.e., focal length) decreases, the eyes must converge, creating eyestrain. One must also take into consideration the fact that as one ages the ability to focus at closer distances is compromised. This phenomenon is called presbyopia and is due to the fact that the lens of the eye loses flexibility with age. The eye (lens) is unable to accommodate and produce clear images of near objects. The nearest point at which the eye can focus accurately, exceeds ideal working distance.²⁵

LOUPES

Magnifying loupes were developed to address the problem of proximity, decreased depth of field, and eyestrain occasioned by moving closer to the subject.

Loupes are classified by the optical method in which they produce magnification. There are three types of binocular magnifying loupes: (1) a diopter, flat-plane, single-lens loupe, (2) a surgical telescope with a Galileian system configuration (two lens system), (3) a surgical telescope with a Keplerian system configuration (prism roof design that folds the path of light).

stereopsis
magnification range
depth of field
resolving power
working distance
spherical and chromatic distortion (i.e., aberration)
ergonomics
eyestrain
head and neck fatigue
cost.

Dentists can increase their resolving ability without using any supplemental device by simply moving closer to the object of observation. This can be accomplished in dentistry by raising the patient up in the dental chair to be closer to the operator or by the operator bending down to be closer to the patient.²⁵ This method is limited, however, by the eye’s ability to refocus at the diminished distance.

As the focal distance decreases, depth of field decreases as well. When one considers the problem of the uncomfortable proximity of the practitioner’s face to the patient, moving closer to the patient is not a satisfactory solution for increasing a clinician’s resolution.

Alternatively, image size and resolving power can be increased with magnification, by magnifying the image through lenses with no need for the position of the object or the operator to change.

The diopter system relies on a simple magnifying lens. The degree of magnification is usually measured in diopters. One diopter (D) means that a ray of light that would be focused at infinity now would be focused at 1 meter (100 cm or 40 inches). A lens with 2 D

* Depth of field refers to the ability of the lens system to focus on objects that are both near and far without having to change the loupe position. As magnification increases, depth of field decreases. Also, the smaller the field of view, the shallower the depth of field. Depth of field is approximately 5 inches (12.5 cm) for a 2x loupe, 2 inches (6 cm) for a 3.25x loupe, and 1 inch (2.5 cm) for a 4.5x loupe. designation would focus to 50 cm (19 inches); a 5 D lens would focus to 20 cm (8 inches). Confusion occurs when a diopter single-lens magnifying system is described as 5 D.

This does not mean 5x power (5 times the image size). Rather, the 5 D designation signifies that the focusing distance of the eye to the object is 20 cm (less than 8 inches) with an increased image size of approximately 2x (2 times actual size).⁷ The only advantage of the diopter system is that is the most inexpensive system, but it is also the less desirable because the plastic lenses that uses are not always optically correct. Furthermore, the increased image size depends on being closer to the viewed object, and this can compromise posture and create stresses and abnormalities in the musculoskeletal system.²⁵

The surgical telescope of either Galileian or Keplarian design produce an enlarged viewing image with a multiple-lens system positioned at a working distance between 11 and 20 inches (28-51 cm). The most used and suggested working distance is between



11 and 15 inches (28-38 cm).

The Galileian system provides a magnification range from 2x up to 4.5x and is a small, light and very compact system (Fig. 32.4).

The prism loupes (Keplarian system) use refractive prisms and they are actually telescopes with complicated light paths, which provide magnifications up to 6x (Fig. 32.5).

Both systems produce superior magnification, correct spherical and chromatic aberrations, have excellent depth of field, and are capable of increased focal length (30-45 cm), thereby reducing both eyestrain and head and neck fatigue. Both these types of loupes offer significant advantages over simple magnification eyeglasses.



Fig. 32.5. **A**, Prism loupes. These loupes have sophisticated optics, which rely on internal prisms to bend the light (Courtesy of Designs for Vision, Inc, Ranonksima, NE, USA). **B**, The headset produced by Zeiss.

The disadvantage of loupes is that the practical maximum magnification is only about 4.5 diameters. Loupes are available with higher magnification, but they are heavy and unwieldy with limited field of view. Using computerized techniques, some manufacturers can provide magnifications from 2.5x to 6x with an expanded field. Nevertheless, such loupes require a constrained physical posture and cannot be worn for long periods of time without producing significant head, neck, and back strain.

THE PROBLEM OF LIGHT

By increasing light levels, one can increase apparent resolution (the ability to distinguish two object close to each other as separate and distinct). Light intensity is determined by the inverse square law, which states that the amount of light received from a source is inversely proportional to the square of the distance. For example, if the distance of the light to the subject is decreased by half, the amount of light at the subject increases four times. Based on the law, therefore, most standard dental operator lights are too far away to provide the adequate light levels required for many dental procedures.

Surgical headlamps have a much shorter working distance (13 inches, 35 cm) and use fiberoptic cables to transmit light, thereby reducing heat to minimal levels. Another advantage of the surgical headlamp is that the fiberoptic cable is attached to the doctor's headband so that any head movement moves the light. Surgical headlamps can increase light levels up to four times that of conventional dental lights (Fig. 32.6).



Fig. 32.6 **A, B.** Surgical Headlight and loupes. Together, these devices can greatly increase a clinician's resolution (Courtesy of Designs for Vision, Inc. Ronkonkoma, NY, USA).

THE OPERATING MICROSCOPE IN ENDODONTICS

It was capable of only one magnification (8x), was positioned on a floor stand and poorly balanced, had only straight binoculars, and had a fixed focal length of 250 mm. This microscope used angled illumination instead of confocal illumination. It did not gain wide acceptance and the manufacturer ceased manufacturing them shortly thereafter their introduction. Its market failure was more a function of its very poor ergonomic design rather than its optical properties, which were actually quite good. .

Howard Selden was the first endodontist to publish a paper on the use of the operating microscope in endodontics.^{1a} His article discussed its use in the conventional treatment of a tooth, not in surgical endodontics.

In 1991 Gary Carr³ introduced an operating microscope with Galilean optics and ergonomically configured for

dentistry with several advantages that allowed for easy use of the scope for nearly all endodontic and restorative procedures. This microscope had a magnification changer that allowed for five discrete magnifications (3.5-30x), had a stable mounting on either the wall or ceiling, had angled binoculars allowing for sit-down dentistry, and was configured with

dentistry with several advantages that allowed for easy use of the scope for nearly all endodontic and restorative procedures. This microscope had a magnification changer that allowed for five discrete magnifications (3.5-30x), had a stable mounting on either the wall or ceiling, had angled binoculars allowing for sit-down dentistry, and was configured with

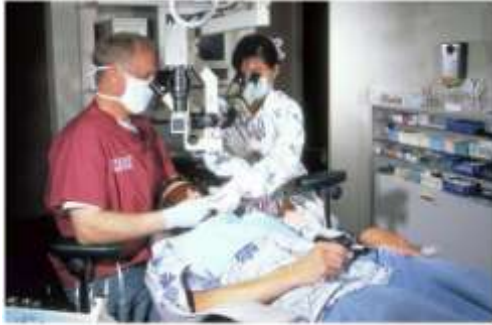

Fig. 32.7. Today's dental microscope allows both the doctor and assistant to view the same field. This microscope is fitted with a 30cd video camera.

adapters for an assistant's scope and video/35 mm cameras (Fig. 32.7). It utilized a confocal illumination module so that the light path was in the same optical path as the visual path and this gave far superior illumination than the angled light path of the earlier scope. This microscope gained rapid acceptance within the endodontic community, and now is the instrument of choice not only for endodontics but for periodontics and restorative dentistry as well. The optical principles of the dental microscope are seen in Figure 32.8.

The efficient use of the microscope requires advanced training. Many endodontic procedures are performed at 10-15x and some requires magnifications as high as 30x. Operating comfortably at these magnifications requires accommodation to new skills that until recently were not taught in dental schools. Among other things, working at these higher-power magnifications brings the clinician into the realm where even slight hand movements are disruptive

Efficient use of an operating microscope in endodontics

Although the operating microscope is now recognized as a powerful adjunct in endodontics, it has not been adopted universally by all endodontists. It is seen by many endodontists as simply "another tool" and not as "a way of practice" that defines how an endodontist works. Although cost is frequently cited as the major impediment, in truth, it is not cost, but a failure to understand and implement the positional and ergonomic skills necessary to effectively use a microscope that has restricted its universal use on all endodontic cases.

The occasional or intermittent use of a microscope on a case results in the very inefficient use of a clinician's time and represents a disruption in the treatment flow of a case

and physiologic hand tremor can be a problem.

In 1995 the American Association of Endodontists formally recommended to the Commission on Dental Accreditation (CODA) of the American Dental Association that microscopy training be included in the new Accreditation Standards for Advanced Specialty Education Programs in Endodontics. At the Commission's January 1996 meeting, the proposal was agreed upon, and in January 1997 the new standards, making microscopy training mandatory, became effective.²⁹

Comment [DC1]: MigrationConfirmed set by Dr. Carr

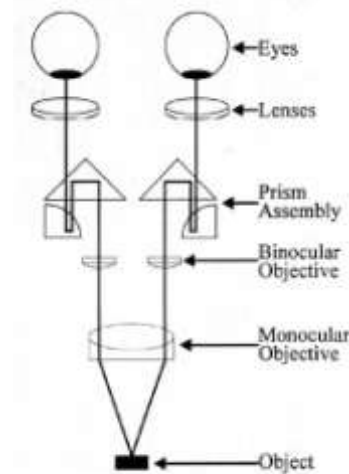


Fig. 32.8. Galilean optics: Parallel optics enables the observer to focus at infinity, relieving eyestrain.

that can only negatively affect the final result. Clinicians who practice this way seldom realize the full advantage of a microscopic approach and never develop the visual and ergonomic skills necessary to operate at the highest level.

The skillful use of an operating microscope entails its use *for the entire procedure* from start to finish. Working in such a way depends upon refinement of ergonomic and visual skills to a very high level.

THE ANATOMY OF THE OPERATING MICROSCOPE

The operating microscope consists of three primary components: the supporting structure, the body of the microscope, and the light source.

The supporting structure

It is essential that the microscope be stable while in operation, yet remain maneuverable with ease and precision, particularly when used at high power.¹² The supporting structure can be mounted on the floor, ceiling, or wall (Fig. 32.9). As the distance between the fixation point and the body of the microscope is decreased, the stability of the set up is increased. In clinical settings with high ceilings or distant walls, the floor mount is preferable. Although it is stated that it can be easily moved from one operatory room to another, in fact, it is very cumbersome to do this and is a very ineffective way to use a microscope.

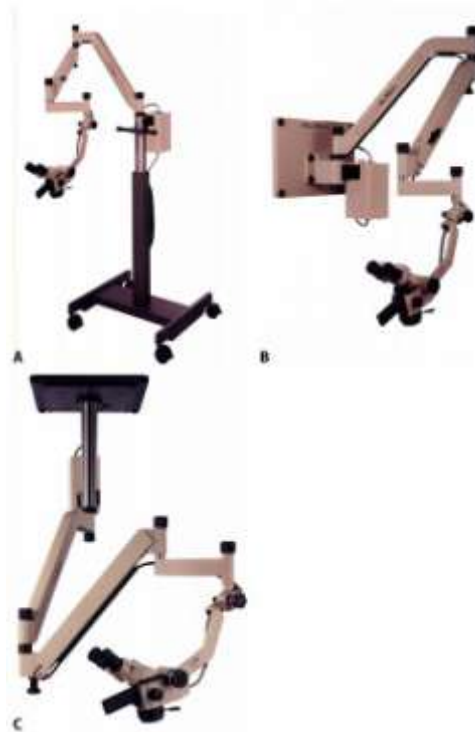

Fig. 32.9. **A.** Global Protege™ Floorstand model. Compact H-base with large locking casters occupies minimal floor space. **B.** Global Protege™ Wallmount model. The extension arm and oblique coupler allow greater maneuverability. **C.** Global Protege™ Ceiling mount model. The ceiling mount is designed to permit maximum range of operation while totally eliminating the use of floor space, and when not in use it folds into a convenient storage position (Courtesy of Global Surgical™ Corporation, St. Louis, MO, USA).

Far preferable is the wall mount or, even better, the ceiling mount. Careful attention should be given to the precise setting of the arms. The built-in springs should be tightened according to the weight of the body of the microscope to establish perfect balance in any position. This permits precise visualization and renders the fine focus unnecessary in the majority of clinical circumstances.¹²

eyepieces, binoculars, magnification changer factor, and the objective lens.

The body of the microscope

The body of the microscope is the most important component of the instrument (Fig. 32.10), and it contains the lenses and prisms responsible of magnification and stereopsis. The body of the microscope is made of

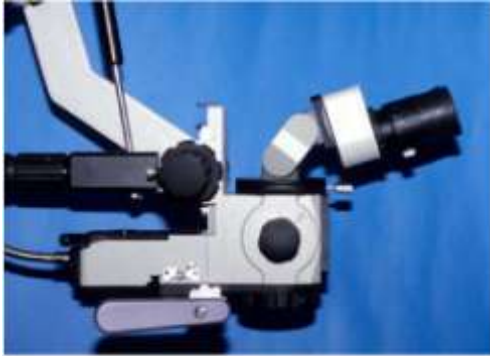

Fig. 32.10. Body of the microscope Global Protege™.

Eyepieces are generally available in powers of 10x, 12.5x, 16x, and 20x. The most commonly used are 10x and 12.5x. The end of each eyepiece has a rubber cup that can be turned down for clinicians who wear eyeglasses. Eyepieces also have adjustable diopter settings. Diopter settings range from -5 to +5 and are used to adjust for accommodation, which is the ability to focus the lens of the eyes. Diopter



Fig. 32.11. Inclined binoculars. The inclined tubes are fixed at 45°.

Magnification changers are available as 3-, 5-, or 6-step manual changers, or a power-zoom changer. They are located within the head of the microscope. Manual step

setting is particularly important when an assistant scope and documentation equipment are used, so that everything is uniformly in focus (par focalled). It is suggested to check the diopter settings frequently. If documentation accessories are used, the eyepiece which is on the same side of the accessory should be provided with a “reticule” that will help to keep the images well centered in the field.

The binoculars contain the eyepieces and allow the adjustment of the interpupillary distance. Their focal length is 125 or 160 mm. They are aligned manually or with a small knob until the two divergent circles of light combine to effect a single focus. Once the diopter setting and interpupillary distance adjustments have been made, they should not have to be changed until the microscope is used by a surgeon with different optical requirements.” Binoculars are available with straight, inclined, or inclinable tubes. Straight tube binoculars are orientated so that the tubes are parallel to the head of the microscope. They are generally used in otology and are not well suited for dentistry. Inclined tubes are fixed at a 45° angle to the line of sight of the microscope (Fig. 32.11). The inclinable tubes are adjustable (Fig. 32.12) through a range of angles and allow the clinician to always establish a very comfortable working position. It is therefore obvious that, even if more expensive, the inclinable binocular is always to be preferred.

changers consist of lenses that are mounted on a turret that is connected to a dial located on the side of the microscope. The magnification is altered by rotating the dial. A power zoom changer is a series of lenses that move back and forth on a focusing ring to give a wide range of magnification factors. Focusing with a power zoom microscope is performed by a foot control or by a manual override control knob located on the head of the microscope. The advantage of the power zoom changers is that they avoid the momentary visual disruption or jump that occurs with manual step changers as the clinician rotates the turret and progresses up or down in magnification. The disadvantages are the following: the excursion from the minimum to the maximum magnification is quite slow, while it is much faster with the manual step changers; the number of lenses is much higher compared to the manual step changers, and this means a greater absorption of light; power zoom changer are much more expensive.


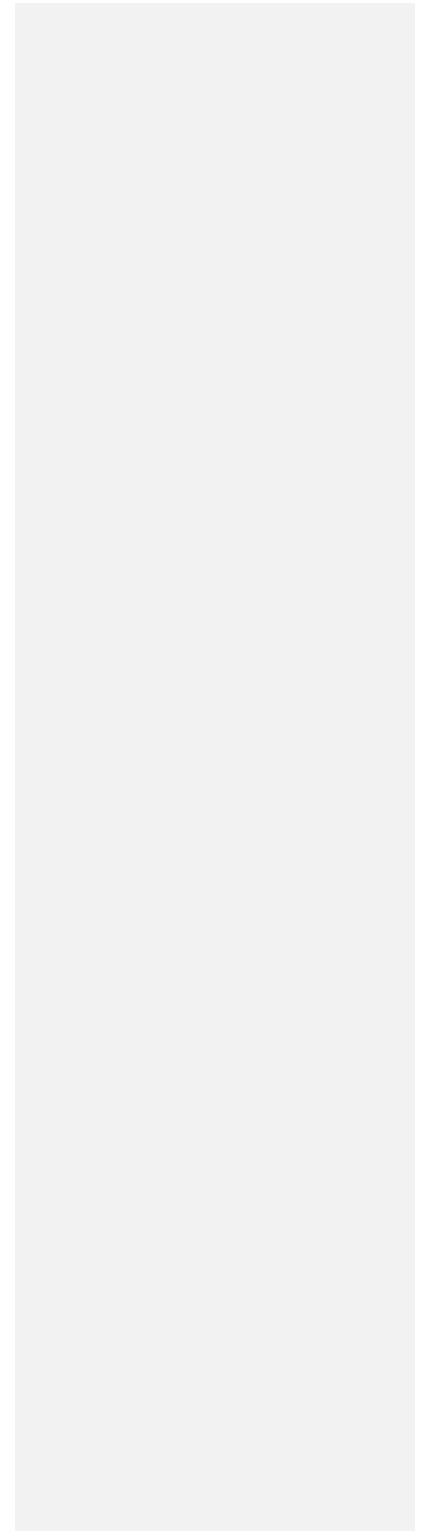


Fig. 32.12. **A-C.** Indrable binoculars (Courtesy of Leica Microsystems, Heerbrugg, Switzerland)

The objective lens is the final optical element, and its



focal length determines the working distance between the microscope and the surgical field. The range of focal length varies from 100 mm to 400 mm. A 200 mm focal length allows approximately 20 cm (8 inches) of working distance, which is generally adequate for utilization in endodontics. There is adequate room to place surgical instruments and still be close to the patient. In periodontics a 250 mm is suggested to give more room to the clinician who may work both on the buccal and palatal side of the same quadrant and who might need to rotate the head of the patient. The objective lens, as well as all the other lenses of the microscope (eyepiece lenses, magnification turret lenses, camera attachment lenses, etc), all have several layers of an anti-reflective coating on both surfaces, which reduces return light loss from normally 2% per lens surface to only 0.5% per lens surface. In other words, the coating is used to absorb only a minimum amount of light in order not to decrease the illumination of the operative field.

The total magnification (TM) of a microscope depends on the combination of the four variables: 1) focal length of binocular (FLB); 2) focal length of objective lens (FLOL); 3) eyepiece power (EP); magnification factor of the changer (MF). The total magnification can be represented by the following formula:

$$TM = (FLB/FLOL) \times EP \times MF$$

For example: Binocular focal length = 125mm
 Objective lens focal length = 250 mm
 Eyepiece magnification = 10x
 Magnification factor = 0.5

$$TOTAL\ MAGNIFICATION = 125/250 \times 10 \times 0.5 = 2.5x$$

Charts are available that explain magnification as it relates to eyepiece power, binocular focal length, magnification factor, and objective lenses." These charts contain valuable information that helps the clinician to select the appropriate optical components to satisfy individual requirements (Tab. II). The information can be summarized as follows:"

- Increasing the power of the eyepieces, magnification increases and the field of view decreases.
- Increasing the focal length of the binoculars,

Table II

	TURRET MAGNIFICATION FACTOR				VARIABLE FACTORS		
	5	10	15	20	Epiece	Binocular	Obj. Lens
T	3.9	4.6	6.7	10	13.3	80	100
	4.3	5.8	8.9	12.8	17.1	80	100
	5.2	6.9	10.0	15.0	16.7	100	100
	6.2	7.7	12.7	18	21.3	100	100
O	6.2	6.8	12.4	18.8	20.9	125	100
	6.7	6.8	13.9	20	26.7	100	100
	6.8	6.8	14.7	20	11.4	80	125
	3.7	4.8	7.3	11	14.6	80	100
A	4.8	6.7	7.1	12.7	14.3	100	125
	4.8	6	8.7	13.7	16.3	100	100
	4.8	5.8	8.8	13.4	17.8	12.5	125
	4.7	7.8	11.4	17.1	22.9	12.5	100
L	2.8	3.2	6	7.8	10	80	125
	3.2	4.2	8.8	9.8	12.8	80	100
	3.1	4.1	8.8	9.3	12.8	100	200
	4	6.3	8	12	16	100	200
M	3.8	6.1	7.8	11.7	18.6	12.5	200
	6	6.7	10	10	20	12.5	200
	2.2	2.8	4.6	6.7	8.9	80	125
	3.8	3.7	8.7	8.8	11.4	80	200
A	4.8	3.7	8.8	8.8	11.2	100	200
	3.8	6.7	7.1	12.7	16.2	100	200
	3.8	4.6	8.8	12.4	13.9	12.5	200
	4.8	6.8	8.8	13.4	17.8	12.5	200
G	2	3.7	6	8	8	80	100
	2.8	3.4	5.1	7.7	10.2	80	200
	3.8	6.4	8	7.8	10	100	200
	3.2	4.2	6.8	8.8	12.8	100	200
H	3.1	6.7	8.8	9.3	13.4	12.5	200
	6	6.3	8	12	16	12.5	200
	1.7	2.8	4.1	6	6.7	80	200
	2.1	2.8	4.2	6.4	8.2	80	200
I	3.1	3.7	4.8	6.4	8.3	100	100
	2.7	3.5	5.3	8	10.8	100	200
	2.4	3.4	5.1	7.8	12.8	12.5	200
	2.4	4.4	6.7	10.1	13.4	12.5	200
F	1.4	1.9	2.8	4.3	6.7	80	100
	1.8	2.4	3.7	5.8	7.3	80	200
	1.8	3.2	3.6	6.4	7.1	100	200
	2.2	3	4.8	6.3	8.5	100	200
C	2.2	3.9	4.6	6.7	8.9	12.5	200
	3.8	3.7	6.8	8.4	11.2	12.5	200
	1.2	1.8	2.3	3.7	6	80	200
	1.8	2.1	3.2	4.8	6.4	80	200
A	1.8	2.7	3.1	4.7	6.2	100	400
	2	2.8	4	6	8	100	400
	1.8	2.6	3.9	5.4	7.8	12.5	400
	2.5	3.3	5	7.5	10	12.5	400

magnification increases and the field of view decreases. Increasing the magnification factor, magnification increases and the field of view decreases. Increasing the focal length of the objective lens, magnification decreases and the field of view increases. In addition, the illumination also decreases because we are farther away from the surgical field. Each time the magnification is increased, the depth of field and the illumination decrease.

Considering all the above factors, a typical microscope with 12.5x eyepieces, 125 mm inclinable binoculars, manual 5-step changers, and an objective lens of 200 mm would allow the clinician to operate comfortably at 20 cm (8 inches) from the operative field and in the magnification range of 3.9x, 5.1x, 7.8x, 11.7x, and 15.6x respectively. As far as the use of different magnifications, it is important to keep in mind that maximum magnification is used to check, and most of the procedures are made at minimum-medium magnification.

In endodontics we don't need microscopes that can provide 20 or even more magnifications since it is almost impossible to work at such high power. As already stated above, working at high magnification the operative field, the illumination, and mainly the depth of field decrease: this in other words means that at maximum magnification the area is extremely reduced, the illumination could be insufficient, and more importantly it is very difficult to keep

the operative field constantly in focus. A little movement of the patient or sometimes just his/her breathing can be

The fine focus can be done manually using the device integrated in the objective lens, or rotating a fine focus knob, which raises the entire body of the microscope, or by an electric foot control.

One might think that working constantly with the microscope will cause eyestrain and eye fatigue. Not only is this not true, but what is true is just the opposite. As a

The light source

The light source is one of the most important features of an operating microscope.¹² Besides optics, the light source is responsible for operating in operative fields that are small and deep like the root canal. This is possible because the microscope provides a powerful coaxial illumination, which means that the light is coaxial with the line of sight and eliminates the presence of any shadows.

Some microscopes provide a double beam of light, so that the operative field gets the light from two different angles. This type of illumination is to be avoided; even though the illumination is apparently double, in reality neither of the two beams of light is coaxial. Therefore it will be impossible to have enough light inside the root canal.

Two light source systems are commonly available: halogen light and xenon light. The halogen light frequently does not provide enough illumination for quality documentation especially at higher powers. The xenon light is much more powerful and provides a brighter light at about 5,000° Kelvin approximating day light. In both cases the light intensity is controlled by a rheostat and cooled by a fan. After the light reaches the surgical field, it is reflected back through the objective lens, through the magnification changer lenses, and through the binoculars and then exits to the eyes as two separate beams of light. The separation of the light beams is what produces the stereoscopic effect that allows the clinician to see depth of field.¹³

Some microscopes are able to focus the light to a smaller diameter. At minimum magnification, the illuminated area is about 6 cm in diameter. The same area is illuminated when we work at medium or maximum magnification, while the area of the operative field is much smaller maybe less than 1 cm. To avoid this and to concentrate the light where it is really useful, some manufacturer produce a

Accessories

enough to be completely out of focus.

matter of fact, operating microscopes possess the additional benefit of Galileian Optics, as they focus at infinity and send parallel beams of light to each eye.^{12,19} With parallel light, the operator's eyes are at rest, as though looking off into the distance, permitting performance of time-consuming procedures without inducing eye fatigue, like we have if we are working with the naked eye at a small distance from the patient requiring convergent optics.

condenser which not only reduces the illumination field size (like any diaphragm can do), but mainly condenses to a small spot the same amount of light that at small magnification is illuminating a bigger area (Fig. 32.13).




Fig. 32.13 **A**, Varifield Illumination Module. A simple slide mechanism allows continuous adjustment, controlling the light field size from 55 mm (**B**) to 15 mm (**C**). As the light field decreases, the brightness actually increases up to three times normal (Courtesy of Global SurgicalTM Corporation, St. Louis, MO, USA).

Some microscopes are built with fixed components and don't allow the insertion any accessories. Some others can be personalized with accessories like the assistant scope and

documentation tools, like a 35-mm and a video camera. To supply light to such accessories, a beam splitter must be inserted in the pathway of light as it returns to the operator's eyes between the binoculars and the magnification changer. The beam splitter divides each path of light into two parts (50:50); one goes to the operator eye and the other goes to the accessory (Fig. 32.14). Usually, half of the light of the left beam goes to the assistant scope, half of the light of



Fig. 32.14. Leica microscope fitted with the inclinable binocular, beam splitter, documentation adaptor (Designs for Vision), 35mm video camera, digital still camera, ring strobe (Nikon SB 29), assistant scope (Global). The beam splitter divides each path of light into two parts: one goes to the operator eye and the other goes to the accessory.

the right beam goes to the documentation accessories. In other words, this means that our dental assistant will see what we see with our left eye, and we will document what we see with our right eye. Furthermore, even though the dental assistant has her binoculars, she cannot have a stereoscopic view because she will see with two eyes the visual field from just the left port of the beam splitter.

Global Surgical Corporation makes a "Virtual Beamsplitter", which splits the light in a ratio of 95% to 5% instead of the traditional 50/50 (Fig. 32.15). The split is done by having a totally reflective coating across a small area of the beam splitter, while the remaining area of the beam splitter is completely transmissive. This implies that the primary surgeon receives 100% of the light across the large area of the beam splitter, and the camera receives 100% of the light across the

A

B




Fig. 32.15. A. The Global 50:50 beam splitter. B. The Global 95:5 virtual beam splitter.

small area of the beam splitter. In practice, the amount of light received by the virtual beam splitter is enough for the assistant scope or for the videocamera, but it is not enough for the 35 mm camera.

The accessories for documentation are the video camera and the 35 mm camera. They can be mounted separately or combined, through specifically designed photo or video adaptors connected to the beam splitter. In case one wants to use both, it is important to keep in mind that the 50% of light that goes to the documentation accessories will be one more time divided in two parts, one for the video camera and one for the 35 mm camera. Designs for Vision (Ronkonkoma, NY) makes a particular adaptor which, instead of mounting a prism that divides the light into two parts, has a mirror which deviates all the light either to the video or to the photographic documentation. With this adaptor, there is no loss of light. The only disadvantage is that it is impossible to take pictures while the video is recording.

While the light provided by the light source of the microscope is enough for video documentation of good quality, it is not enough for the 35 mm camera to take good pictures. For this reason, it is usually necessary to supplement the microscope's lighting system by adding a

strobe over the objective lens. Several strobes are commercially available and can be adapted to the operating microscope (Fig. 32.16). The digital camera can also

download the images directly into a computer, allowing the rapid organization of a rich database of images.



Fig. 32.16. Another view of the microscope of Fig. 32.14. The digital camera is connected with a strobe.

The video camera can be connected to a monitor, a videotape recorder, and a video printer. The monitor can be used not only to motivate the patient, who can see the entire videotaped procedure, but mainly to the second surgical assistant, who can follow the surgical procedure and give to the operator the right instruments at the right moment. Looking at the monitor, the dental assistant can also work as a video director, and pause the recording if he or she thinks the picture is off center or out of focus.

Photo and cine adaptors are available with different focal length, so that the clinician can choose the one that will allow the recording of an image with the same magnification and field of view as seen through the microscope.

Other important accessories are the eyepiece with the reticle and the assistant scope.

An eyepiece with a reticle field can be substituted for a conventional eyepiece and can prove an invaluable aid for alignment during videotaping and 35 mm photography.⁹

Very useful is the assistant scope (Fig. 32.17), which allows the assistant to “assist” the operator during the entire procedure. Particularly during surgical endodontics, the dental assistant can do

B

C

A

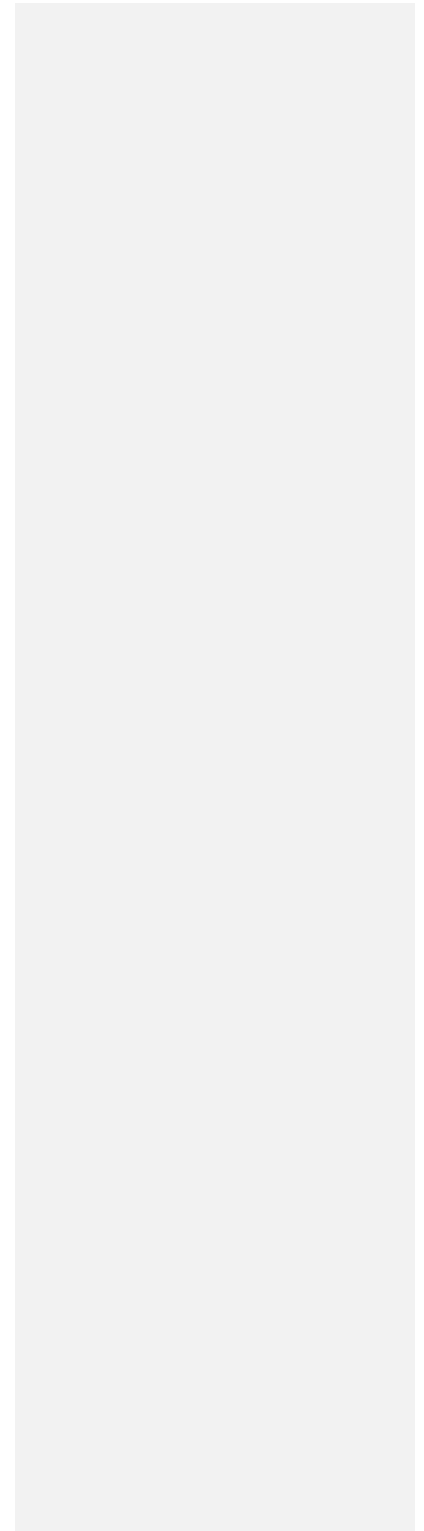

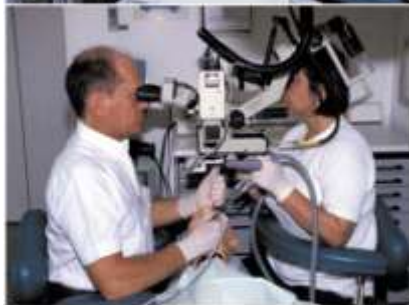
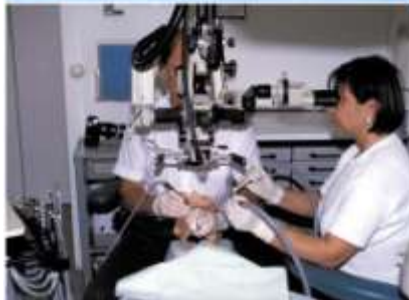

Fig. 32.17 A. The Global assistant scope allows the assistant to be positioned at "3 o'clock" when the operator is sitting both at "12 o'clock" (B) or at "9 o'clock" (C).

The Laws of Ergonomics

An understanding of efficient work flow using a microscope entails a knowledge of the basics of ergonomic motion. Ergonomic motion is divided up into five(5) classes of motion:

1. Class I Motion: moving only the fingers
2. Class II Motion: Moving only the fingers and wrists

her job much more precisely looking through the assistant scope, compared to just looking at the monitor. The second assistant of surgical endodontics will follow the procedure through the monitor, while the first assistant is controlling the bleeding with the suction tips using the auxiliary articulating binocular (Fig. 32.18).

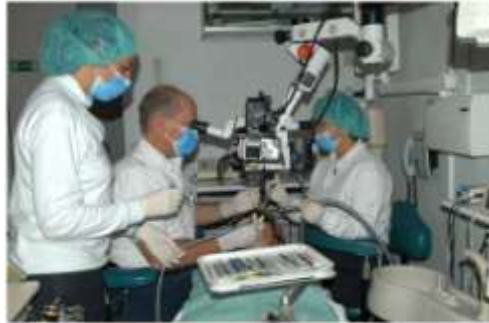

Fig. 32.18. Surgical endodontics is a "teamwork" the first assistant is controlling the bleeding with the suction tips, while the second assistant is standing up to the right of the operator and she puts every single instrument among the fingers of the operator, following the procedure through the monitor.

3. Class III Motion: Movement originating from the elbow
4. Class IV Motion: Movement originating from the shoulder
5. Class V Motion: Movement that involve twisting or bending at the waist

Positioning the microscope

The introduction of the operating microscope in a dental office requires significant forethought, planning, and an understanding of the required ergonomic skills necessary to use the microscope efficiently. Proper positioning, for the clinician, patient, and assistant is absolutely necessary. Most problems in using a microscope in a clinical setting are related either to positioning errors or lack of ergonomic skills on the part of the clinician. It is possible to work at the microscope in complete comfort with little or no muscle tension if proper ergonomic guidelines are followed.

In chronological order, the preparation of the microscope involves the following maneuvers:

- 1 Operator positioning
- 2 Rough positioning of the patient
- 3 Positioning of the microscope and focusing
- 4 Adjustment of the interpupillary distance
- 5 Fine positioning of the patient
- 6 Parfocal adjustment
- 7 Fine focus adjustment
- 8 Assistant scope adjustment

1) Operator positioning

The correct operator position for nearly all endodontic procedures is directly behind the patient at the 11 or 12 o'clock position. Positions other than the 11 or 12 o'clock position (for example 9 o'clock) may seem more comfortable when first learning to use a microscope, but as greater skills are acquired, changing to other positions rarely serves any purpose. Clinicians who are constantly changing their positions around the scope are extremely inefficient in their procedures.

The operator should adjust the seating position so that the hips are 90 degrees to the floor, the knees are 90 degrees to the hips and the forearms are 90 degrees to the upper arms. "The operator forearms should lie comfortably on the armrest of the operator's chair and his or her feet should be placed flat on the floor (Fig. 32.19). The back should be in a neutral position, erect, perpendicular to the floor, with the natural lordosis of the back being supported by the lumbar support of the chair, with the eyepiece

inclined so that the head and neck can be held at an angle that can be comfortably be sustained. This position is maintained regardless of the arch or quadrant being worked on. It is the patient who is moved to accommodate this position. After the patient has been positioned correctly, the arm rests of the doctor's and assistant's chairs are adjusted so that the hands can be comfortably placed at the level of the patient's mouth. The trapezius, sternocleidomastoid, and erector spinae muscles of the neck and back are completely at rest in this position.

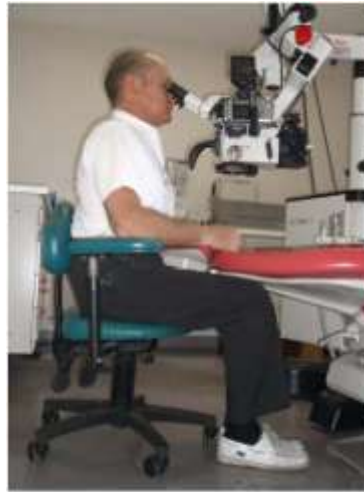

Fig. 32.19 Correct position at the microscope.

A common problem in establishing proper posture in microscopic dentistry results from chair headrests that position the patient's head too far from the doctor's waist. Such positioning will result in the doctor having to bend forward from the waist (Fig. 32.20). Holding this position for long periods results in muscle fatigue and muscle splinting, with resultant pain and chronic injury. Most dental chairs that have too long a headrest are best modified by simply removing the headrest and placing a soft pillow in its place. (pic from carr)

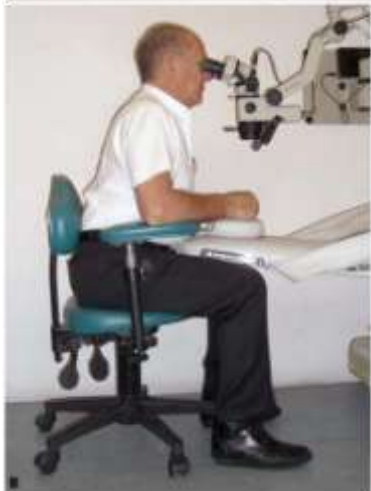

Fig.32.20. **A.** Body of the microscope without the Carr Binocular Extender. **B.** Poor position: holding this position, leaning forward, for long periods can cause muscle fatigue.



Fig.32.21. The Carr Binocular Extender can be added to any Global microscope.

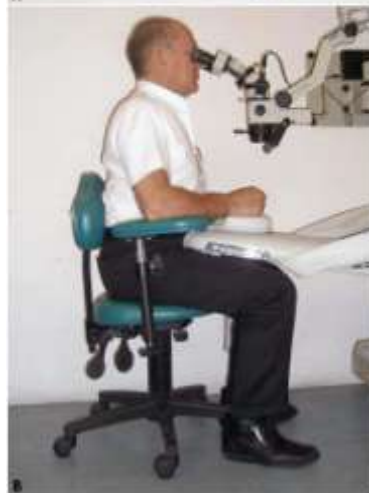

Fig. 32.22 **A.** Body of the microscope with the Carr Binocular Extender. **B.** Good position: aided by the chair's lumbar support, the clinician's back is erected (perpendicular to the floor), a position that is maintained regardless of the quadrant being worked on.

Both Global Surgical Corp. and Zeiss have adapters (Fig. 32.21), which solves the problem of the caudally placed patient or the doctor with expanded girth. These adapters allow the doctor to sit upright even if the patient's head cannot be ideally placed. The adapter can be easily added to these microscopes along with inclinable binoculars (Fig. 32.22). It is attached between the binocular head and microscope body or beamsplitter.⁶

2) Rough positioning of the patient

The patient is placed in the Trendelenburg position and the chair is raised until the patient is in focus. The main advantage of the Zeiss Pro-Ergo microscope is that the patient height can be varied to fit the most comfortable position because the focal length of the microscope can be optically changed simple by activating the zoom control. This ability to easily change the focal length of the lens makes patient positioning to the ideal height possible on nearly all patients.

3) Positioning of the microscope and fine focus

After turning on the light of the microscope, the microscope should be maneuvered so that the circle of light shines on the working area. Knowing the focal length of the objective lens, the operator moves the body of the microscope approximately to the working distance and then, looking through the eyepiece, moves the microscope up and down until the working area comes into focus. During this maneuver, the fine focus device of the objective lens should be in an intermediate position in order to allow a wide range (20 mm) during the fine focusing of the operative field. The inclinable eyepiece is now adjusted so that the operator's head and spine can maintain a comfortable position with the working area in focus.

4) Adjustment of the interpupillary distance

Looking through the binocular, each eye sees a small circle of light. The interpupillary distance should be now adjusted by taking the two halves of the binocular head of the microscope (Fig. 32.23), and moving them apart and then together, until the two circles are combined and only one illuminated circle is seen. With some microscopes, this maneuver is made moving a knob located on the binocular. Adjustable rubber cups extend from the ends of the eyepieces. Those who wear glasses should have the cups in the lowered position and those who work without glasses should work with the cups in the raised position.

5) Fine positioning of the patient

Now it is necessary to make little movements with the back of the dental chair, in order to position the patient in the definitive position. With this in mind, one should take into consideration that in nonsurgical endodontics 100% of the work at the microscope is done in indirect vision through the mirror. Therefore, the definitive position of the

patient depends on the angle that the light of the microscope has to make in order to illuminate the root canal where the clinician is working. If the light beam is perpendicular to the floor and the mirror is at 45° to the light, the patient must be positioned in order to allow the light to enter the root canal to be treated. In other words, the root canal of the tooth to be treated must be positioned at 90° to the light beam, while the mirror is at 45° angle. Therefore, to work in a maxillary root canal the patient should be horizontal, parallel to the floor (Fig. 32.24A); to work in mandibular root canal the patient should be in "Trendelenburg" position, which means with the head slightly lowered to the pelvis (Fig. 32.24B).



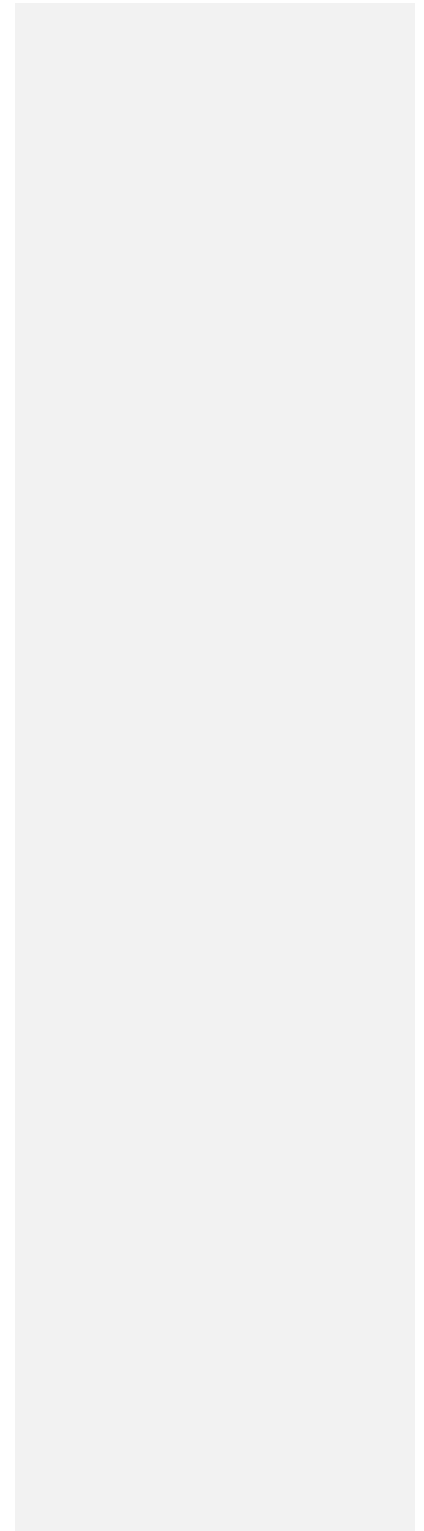
Fig. 32.23 A, B. The binocular allows to change the interpupillary distance in a range of 55 – 90 mm.

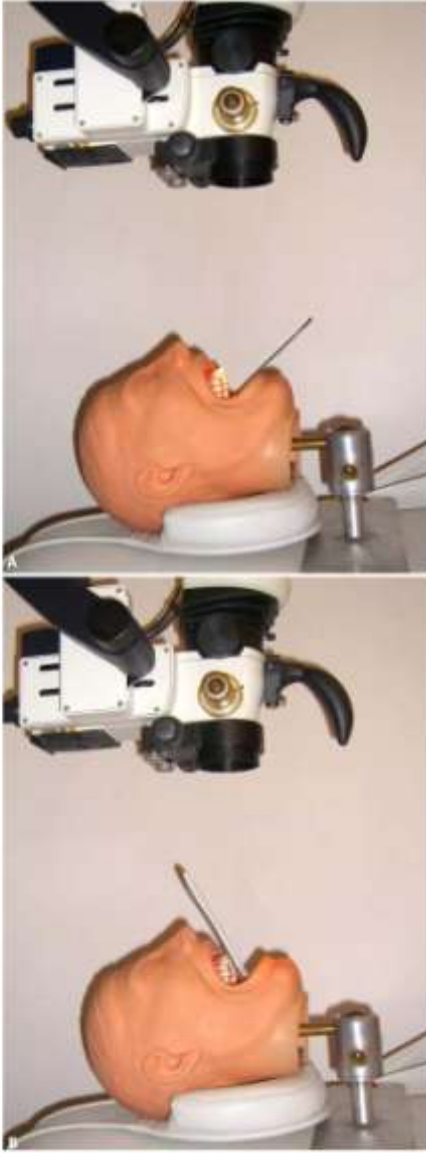

Fig. 32.24. When the operator is in the correct position, the light beam is perpendicular to the floor, the mirror is at 45° to the light and the root canal must be parallel to the floor. **A**, Pathway of the light beam to enter a root canal of the upper arch. **B**, Pathway of the light beam to enter a root canal of the lower arch.

6) parfoCal adjustment

The eyepieces should now be individually adjusted (Fig. 32.25) so that the focused view of the working area will stay



sharp as the magnification setting is changed. This process is called parfocaling, and it is important to perform it correctly especially when the assistant scope or the documentation accessories are mounted on the microscope. In fact, it is mandatory that when the working area is in focus for the operator, it is also in focus for the assistant, for the video camera or for the still camera.



Fig. 32.25. Each eyepiece has several settings for the parfocal adjustment. Also, the position of the rubber cups may change: lower position if the operator is wearing glasses (A); raised position if the operator is not wearing glasses (B).

These are the steps to follow for the parfocal adjustment:

- 1 Position the microscope above a flat, stationary surface.
- 2 Using a pen or pencil, make an "X" on a piece of white paper to serve as a focus target and place it within the illumination field of the microscope.
3. Set both the eyepiece diopter settings to "0".

Also set assistant's eyepieces (if any) to "0".

- 1 Set the microscope near the middle of its focus range.
- 2 Position the microscope vertically at a convenient view height and so that the target is within the view range.
- 3 Set the microscope on its highest magnification setting (zoom in), and focus using the fine-focus control until a sharp image is obtained.
- 4 Being careful not to physically shift the microscope position, change the magnification setting to its lowest position (zoom out). Focus left and right eyepieces, one at a time, by turning the diopter ring until the image is clear and sharp. Tighten the diopter lock button to lock in this position, and record the setting for future use.
- 5 Each operator will have their own particular settings that are to be dialed in whenever that particular operator uses the microscope.
- 6 This procedure does not have to be repeated by the same operator each time the microscope is used, but rather the diopter settings noted the first time the parfocaling procedure was performed by that operator should be used. However, due to changes in eye correction associated with time, it is recommended that this procedure be repeated by the operator once or twice per year.

7) fine focus adjustment

Installing an operating microscope should also be considered a new ergonomic organization in the dental office. This should also include the dental chair, which should have its back thin enough to allow the operator to position his or her legs underneath. In fact, the fine focus and even more, changing the focused area from one plane to another dipper inside the root canal, is made lifting just a few millimeters the entire back of the dental chair with the operator's knee (Fig. 32.26). This way, working inside a root canal, the area in focus can be changed from the orifice level to the deepest point of the canal itself without using the hands and without moving the hands from the working area.

8) assistant scope adjustment

Once the clinician has completed all the above mentioned procedures, the dental assistant will perform the same adjustments on the binocular and on the eyepieces, obviously without changing the position of the microscope.

Usually, the adjustment 4, 6 and 8 are made only once, while the others are made each time the operator starts a new endodontic procedure.

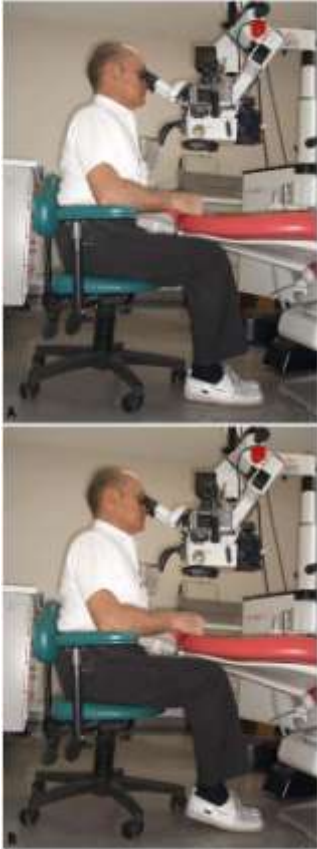

Fig. 22.26 **A, B.** The fine focus is made lifting for a few millimeters the entire back of the dental chair with the operator's knee.

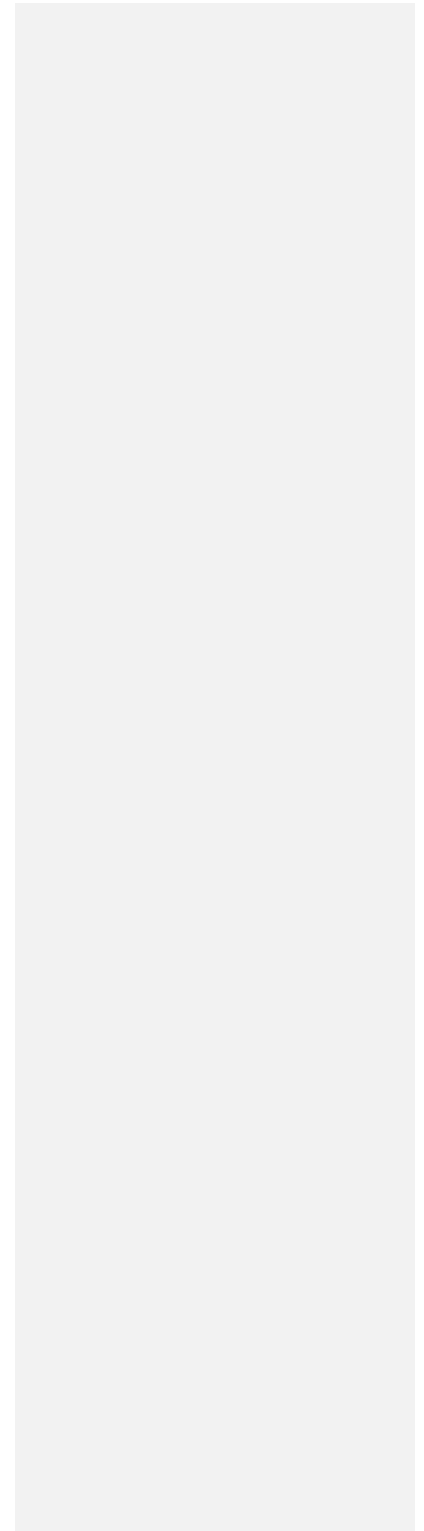
Ergonomics and the Microscope

Basic ergonomic principles actually dictate the design of a microscopic-centered practice. Questions pertaining to the placement of the patient chair, how to construct the back and side walls, what type of cart to use and where to position it, where to place the cabinets, and where to mount the microscope cannot be completely answered without first answering the question of “how a doctor works.” “How you work” is really just an analysis of a clinician’s motion which is the subject of the Science of Ergonomics.

To develop the highest efficiency, most endodontic

The organizing ergonomic principle of a microscopic-centered practice is called “circle of influence”. This principle states that all necessary equipment and supplies needed by both the doctor and assistant are within an arm’s reach of either, preferably with nothing more than a Class III motion. So all instruments, suction, handpieces, indeed everything needed for the procedure, is no more than an arm length away. This design principle therefore places significant design constraints on the width of the operatory and the design of the back and side walls. An ergonomically designed back wall is shown in Fig X.

procedures should be performed utilizing only Class I and Class II motions. Therefore the operator should never lose



the distance relationship between his or her hands and the mouth of the patient and every instrument should be positioned by the dental assistant not just in his or her hands, but in his or her fingers. This is very easy to accomplish if the doctor restricts the motions to only Class I and Class II motions. When Class III motions creep in, inefficiencies increase exponentially.

In nonsurgical endodontics, most procedures are made using indirect vision via a mirror (Fig. 32.27). From the mirror, the light will be reflected to enter inside the root canal. Sometimes the mirror can be positioned close to the crown of the tooth where the clinician is working, but most

of the time the mirror is positioned far away from the tooth, even outside the mouth, on the cheek, just to make room for the instruments or handpieces (Fig. 32.28). The mirror should be positioned far enough to allow the head of the handpiece to enter the working field and not to obstruct the operator's view. In some instances, the operator's view is improved by using a buccal photographic mirror instead of a mouth mirror. The buccal photographic mirror provides a broader viewing area. It also enhances the operator's ability to reposition the reflected image allowing for ideal handpiece placement.

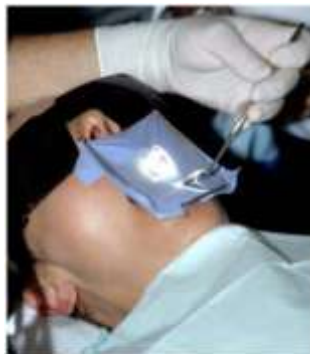

Fig 32.27. The light beam is always oriented on the mirror and then enters the root canal.

Once the ideal position is established, the operator places the microscope on one of the lower magnifications to locate the working area in its proper angle of orientation. The image is focused and stepped up to higher magnifications if desired.²¹

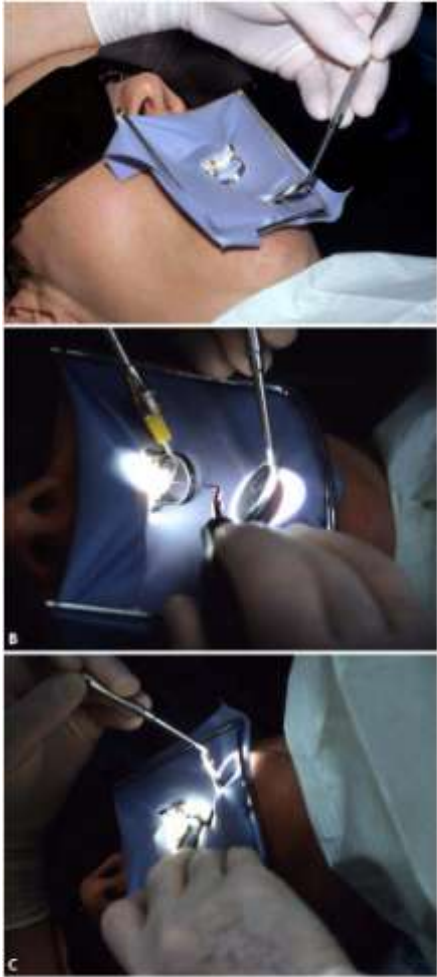

Fig. 32.29. **A-C.** The mirror is positioned on the cheek to make room to instruments or to handpieces.

The use of the operating microscope in endodontics

Diagnosis

The operating microscope enables the endodontist to assess the marginal integrity of restorations and to detect cracks or fractures.

The crack can be coronal, responsible for the “cracked tooth syndrome” or it may be found after the removal of a restoration. Once the tooth has been accessed, cracks can also be detected on the floor of the pulp chamber (Fig. 32.29A). For optimal visibility, it is important to control the

hydration of the dentin. If the dentin is too dry, the texture appears white and chalky, and the crack will not be visible; if the dentin is too wet, the reflection of water on the surface will mask the crack. To precisely adjust the drying of the dentin surface, a Stropko irrigator (Sybron Dental, Orange, California) can be used.¹² The use of a dye like methylene blue or a caries detector can be very helpful to better visualize the crack and to follow its length to its termination. (Fig. 32.29B).

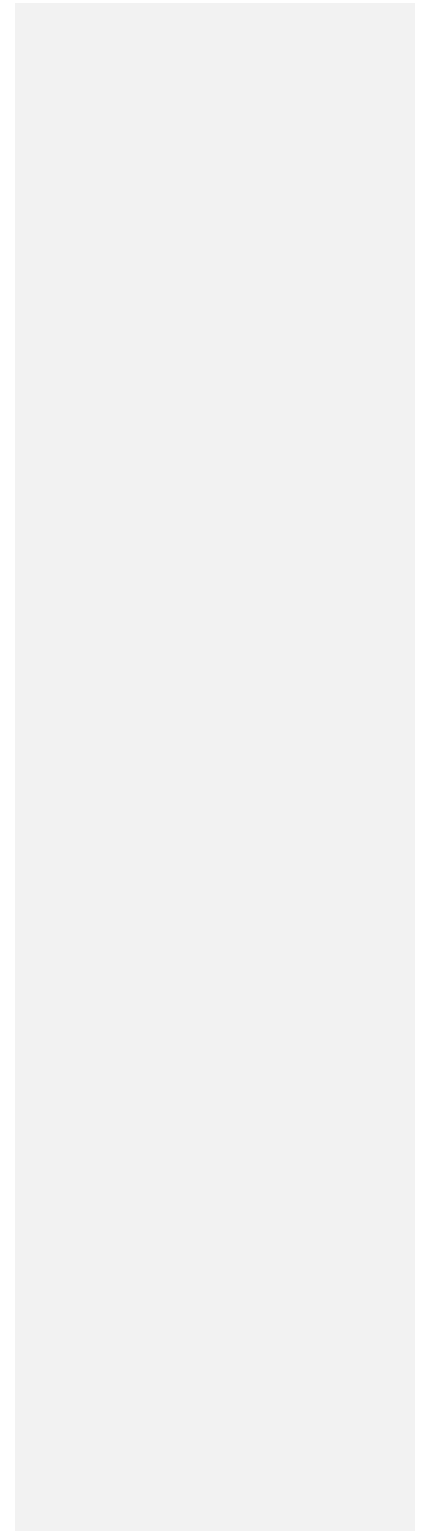

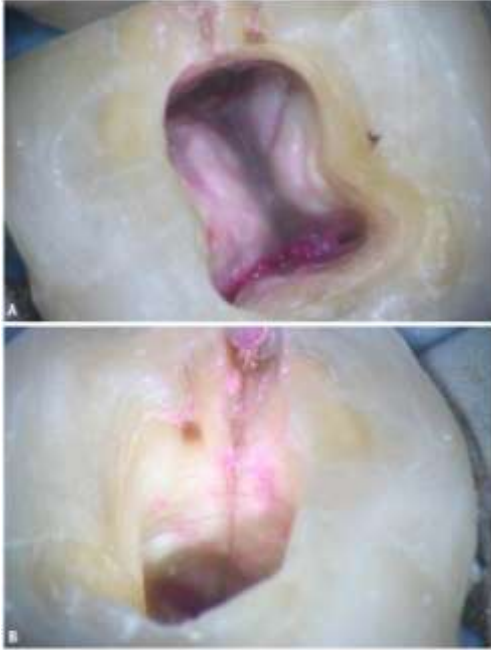


Fig. 32.29: The use of a dye is very helpful to better visualize a crack on the floor of a pulp chamber (A) and to follow its length deep inside the root canal (B).

The operating microscope can also be useful to detect radicular cracks and fractures, avoiding the necessity of exploratory surgery. The diagnosis can be made both by examining the external surface of the root (Fig. 28.96) or examining the internal wall of the root canal (Fig. 28.97) after the removal of the old filling material. In many

instances, the width of the crack is merely that of a hairline and would remain unnoticed without the use of the operating microscope.

If the microscope is equipped with the documentation accessories, a video print can be recorded and presented to the patient or to the referring dentist.¹²

Locating the canal orifices

Accessing the pulp chamber and locating the canal orifices constitute important visual phases of endodontic therapy.¹² Errors at this level will compromise the entire treatment. The operating microscope has proven to be indispensable for the localization of coronally obstructed canals. There is no longer any need for guesswork when searching for calcified canals or canals occluded by restorative materials. The microscope can bring the practitioner right into the pulp chamber floor, with high-intensity light revealing in intimate detail an area that was once under-illuminated and which required guesswork and great caution. Practitioners can proceed with confidence and skill because they can see. Subtle and minute differences in color and calcification patterns become immediately obvious, serving as a road map in removing the obstructions.³ Small instruments are used under the microscope to localize the canal orifices, like the JW-17 (C K Dental Specialties) or the Micro Opener (Densply Maillefer) (Fig. 32.30).

The initial step is represented by the complete removal of the roof of the pulp chamber. This procedure is accomplished by using ultrasonic tips in combination with a brush-cutting action to safely eliminate the secondary dentin overlying the orifices and the pulpstones that may be present in the pulp chamber. Pulp tissue changes with age, repeated restorative procedures, trauma from injury, and occlusal wear by depositing layers of amorphous calcified dentin. In a chamber that has obliterated itself with secondary and tertiary dentin, the possibility of perforating the floor during endodontic coronal access (Fig. 32.31, 32.32) becomes a real concern.² Unless one is using high levels of magnification when approaching the floor of the pulp chamber, it is difficult to discern the roof of the chamber from the natural floor. Proceeding blindly

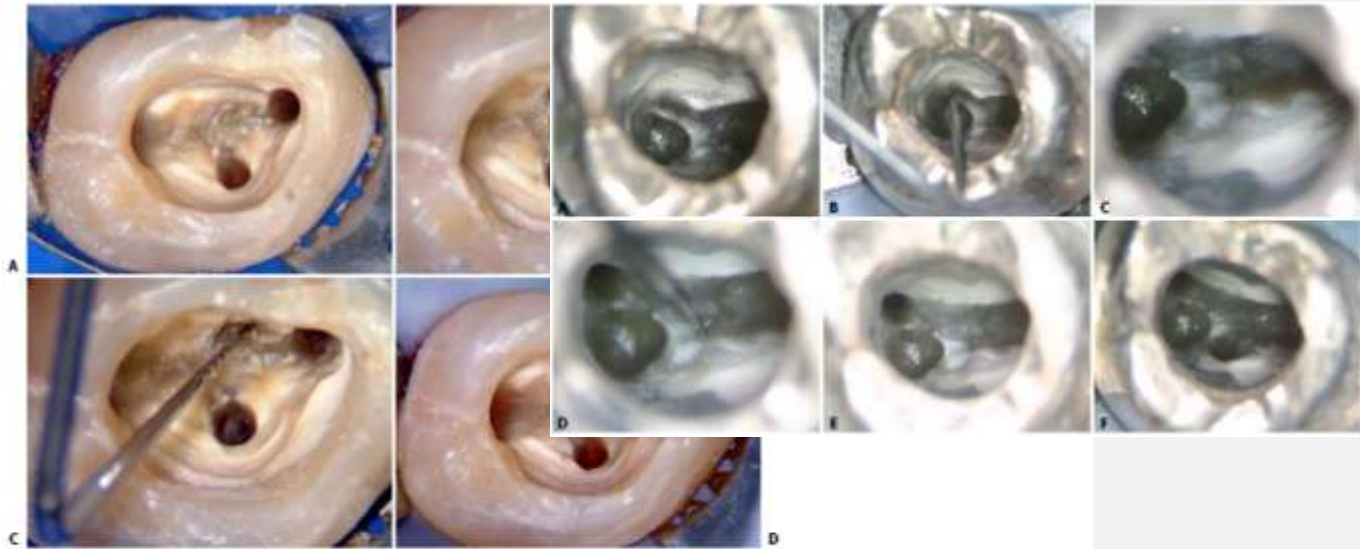


Fig. 32.30. **A-D.** The use of the endodontic explorer JW 117 (CK Dental Specialties, Inc.) and then the Micro Opener (Dentsply Mallefer) are very helpful to locate the orifice of MB2 in the upper first molars.



C. The mesio-buccal canal has been shaped. **D.** The orifice of the disto-buccal canal is now evident. **E.** The Micro Opener is entering the disto-buccal canal. **F, G.** The canals of this molar have been cleaned and shaped. Now is even more evident where the other dentist was looking for the canal orifices.

Fig. 32.31. **A.** In the attempt to locate the buccal canals, the previous dentist was almost making a perforation of the pulpal floor of this upper second molar. **B.** The Micro Opener is locating the mesio-buccal canal.

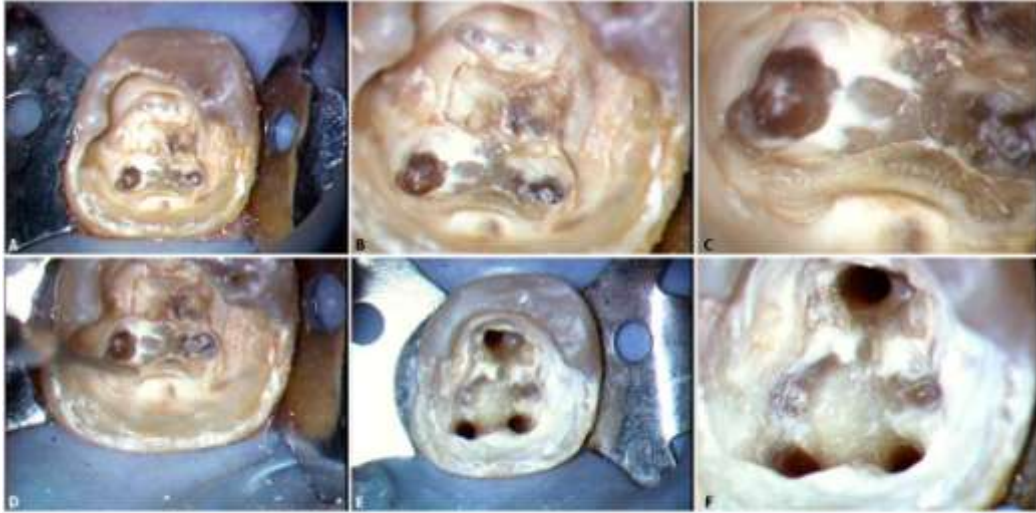

Fig. 32.32. **A**, In the attempt to locate the canals, the previous dentist was almost making a perforation of the pulpal floor of this lower second molar. **B**, At higher magnification it is possible to recognize the calcification hiding the orifice of the three canals. **C**, Note the difference in color and texture of the calcification which is covering the orifices of the mesial canals and the isthmus. **D**, An ultrasonic tip is removing the calcification. **E, F**, The three canals after cleaning and shaping.

without the aid of magnification invites perforation and subsequent failure.²

Common “aberrant” canals frequently seen are the MB1/MB2/MB3 (Fig. 32.33) and the DB1/DB2 (Fig. 32.34) of maxillary molars, and the DB1/DB2 and the MB1/MB2/ML of mandibular molars (Fig. 32.35).⁵ According to recent studies,^{13a} the second canal of mesiobuccal roots is present and can be clinically negotiated in almost 100% of cases. If we compare this result with those published 10 or 15 years before, we can conclude that the higher percentage of these findings today is due to nothing else than the use of the operating microscope (see Chapter 11).

Retreatment

The biggest advantage in using the microscope is during retreatment. To perform a retreatment can be as simple as the removal of gutta-percha from a poorly obturated canal to more complex, delicate and time consuming procedures, like removing screw posts, separated instruments, silver

points, amalgam pins, carbon fiber posts, or repairing a perforation or obturating an immature open apex.

Before the introduction of the operating microscope, everything in endodontics was performed using tactile sensitivity, so that the clinician could “feel” the presence of a problem, like a ledge, a blockage, a broken instrument, a perforation, and the solution to that problem was never predictable.

Until recently, instruments separated within the canal were treated by attempting to bypass the fragments (Fig. 32.36). This method was not only time consuming, but in many instances could increase the risk of separating a second instrument or perforating the root.¹⁶

With the use of the operating microscope every challenge existing in the straight portion of the root canal system, even if located in the most apical part, can be easily seen and then resolved, thanks to magnification and coaxial illumination. In a case of a broken instrument, for instance, the fragment can be visualized and then with ultrasonic vibrations can be removed, without damaging the root (Figs. 32.37, 32.38).

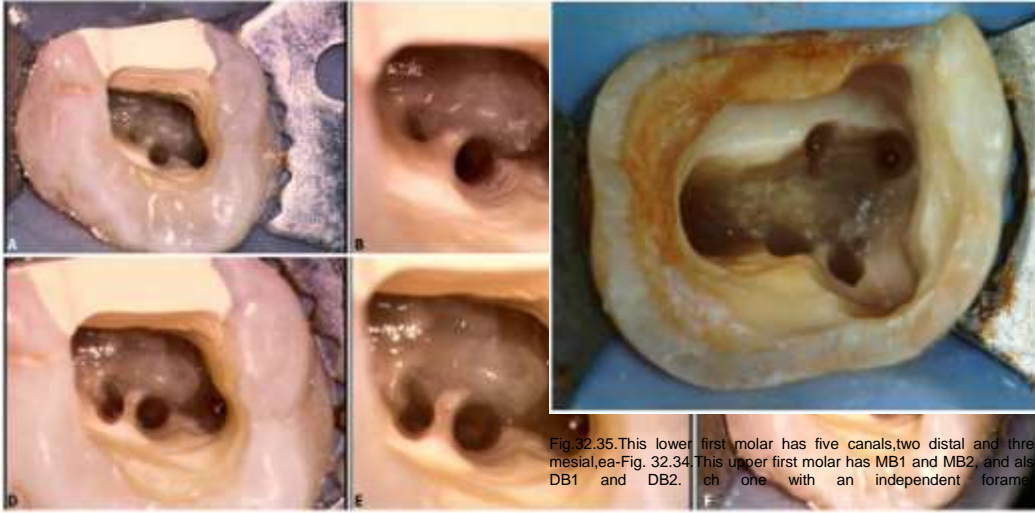
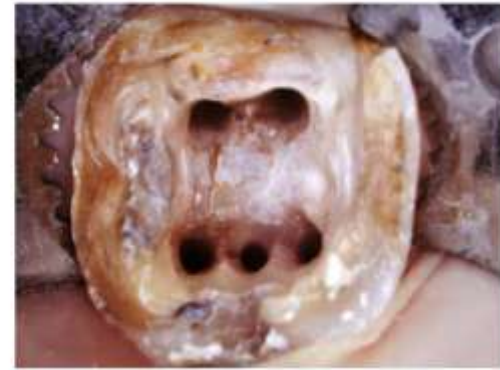
Fig. 32.35. This lower first molar has five canals, two distal and three mesial, ea- Fig. 32.34. This upper first molar has MB1 and MB2, and also DB1 and DB2. ch one with an independent foramen.

Fig. 32.33. A-E. This upper first molar has three mesio-buccal canals. MB1 and MB2 have independent foramina, while MB2 and MB3 have a common foramen, since they are joining together.



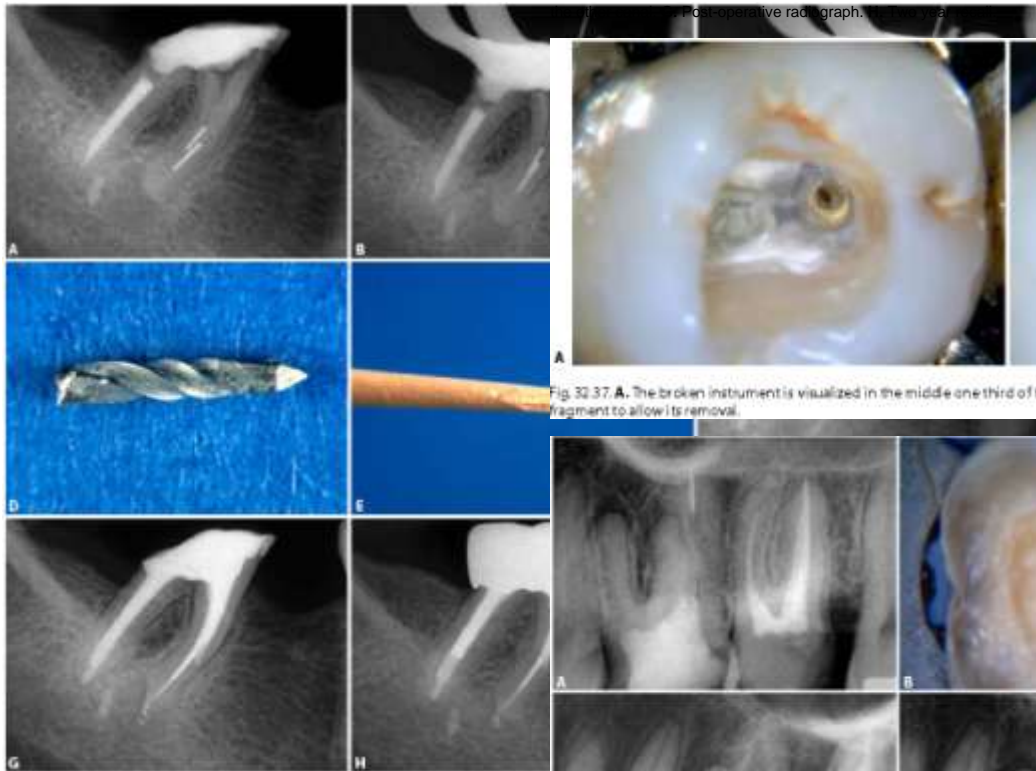



Fig. 32.36. **A.** Two broken instruments are present in the mesial root of this lower second molar. **B.** A #10 K File is bypassing the broken instrument in the mesio-lingual canal. **C.** Just enlarging the canal around, the fragment has been removed from the mesio-lingual canal. **D.** A #10 K File is now bypassing the broken instrument in the mesio-buccal canal. **E.** A gutta-percha point has been inserted in the mesio-lingual and then the K File has been introduced in the mesio-buccal, to detect if the canals are joining together: the impression left on the gutta-percha from the file is confirming that the two canals have a common foramen, therefore it is useless trying to remove the second fragment from the mesio-buccal canal. **F.** The gutta-percha is condensed in the mesio-lingual canal and now is in contact with the broken instrument in

Removing fractured instruments

Separation of an instrument inside the confines of the canal is one of the most vexing problems in endodontics. Iatrogenic accidents of this sort subject the patient and treating doctor to harmful stress levels, provide the legal profession with cases and frequently lead to further damage in attempting to remove or bypass the obstruction.

Traditionally, fractured instrument cases are handled by attempting to bypass the instrument with other instruments, thereby running the risk of perforation or the separation of additional instruments. Other methods rely on trephine burs or extractors using cyanoacrylic glue (Figs.

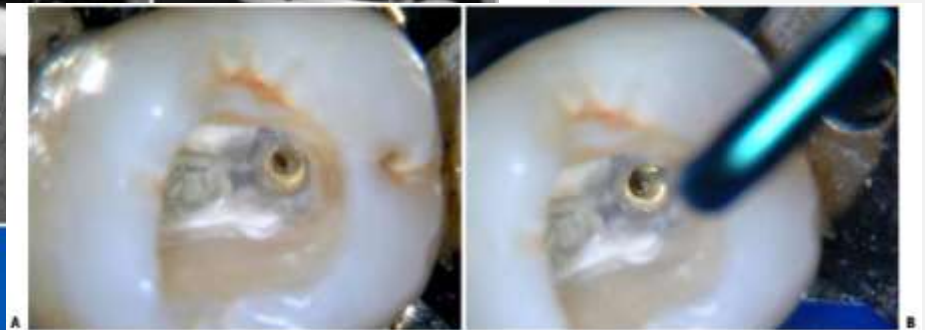

Fig. 32.37. **A.** The broken instrument is visualized in the middle one-third of the root canal. **B.** The ultrasonic tip is transmitting vibrations to the fragment to allow its removal.

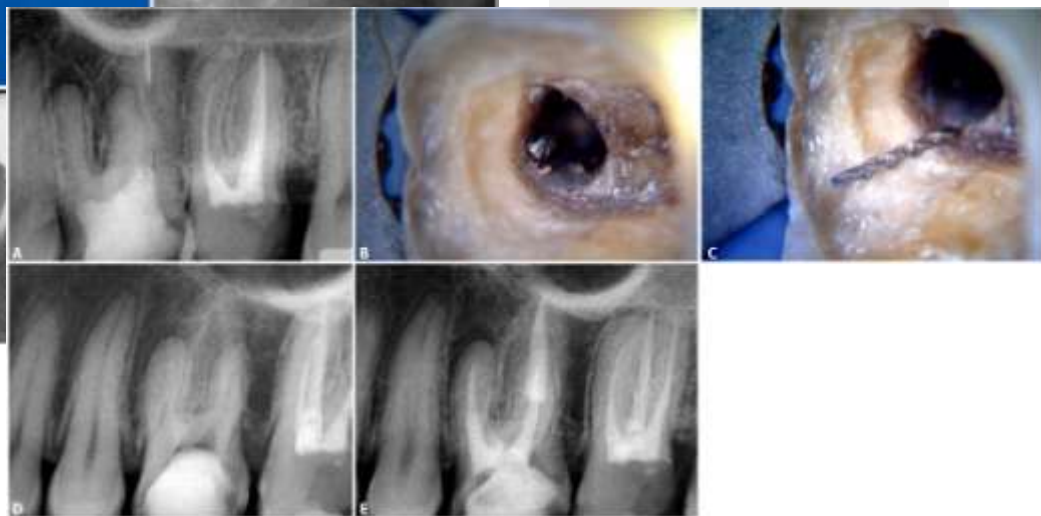


Fig. 32.38. **A.** A broken instrument is at the apex of the palatal root of this upper left first molar. **B.** Using the ultrasonic tip, the fragment has been dislodged and now is close to the canal orifice. **C.** The fragment is now in the pulp chamber. **D.** The fragment has been removed. **E.** Post-operative film.

32.39, 32.40) or pinch-pressure devices (Figs. 32.41, 32.42) to remove the offending instrument. These methods are ingenious, but unfortunately the scale of these devices is often too large for the task and frequently results in perforations or gross destruction of root structure.

Using the operating microscope and a specially designed ultrasonic unit and tips, most instruments can now be easily removed. The instrument is visualized using high magnification. Then a specialized ultrasonic tip is energized, creating a trough around the coronal 2mm of the instrument. The doctor has commanding visual control at all times during this procedure, resulting in minimal loss of root dentin.

After the troughing procedure, the instrument is vibrated

with the side of the tip. It will begin to spin and move coronally because of its tapered shape. It can then be removed using microsurgical forceps that can be manipulated in the pulp chamber because of their small size.

Instruments large and small can be removed in this manner whether they are in the coronal, middle or apical third of a straight root. Instruments separated apical to severe curvatures are not good candidates for this procedure.³

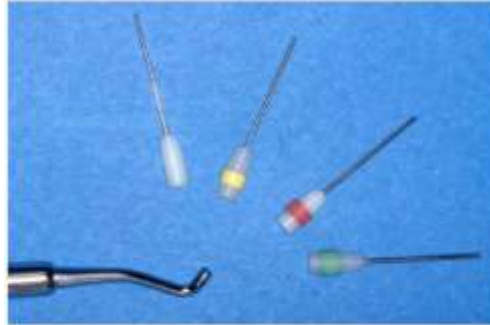

Fig. 32.39 The Cancellier kit.

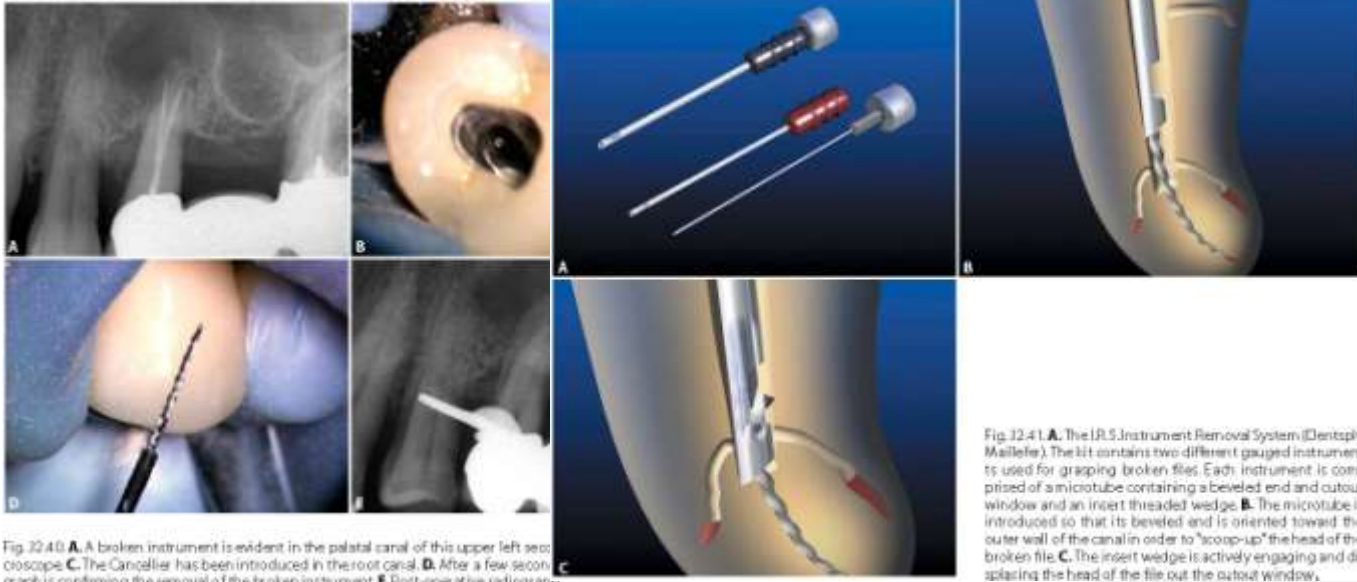

Fig. 32.41 **A.** A broken instrument is evident in the palatal canal of this upper left second premolar. **B.** The Cancellier has been introduced in the root canal. **C.** After a few seconds of rotation, the instrument is removed. **D.** After a few seconds of rotation, the instrument is removed. **E.** Post-operative radiograph.

Fig. 32.41 **A.** The I.R.S. Instrument Removal System (Dentsply Maillefer). The kit contains two different gauged instruments used for grasping broken files. Each instrument is comprised of a microtube containing a beveled end and cutout window and an insert threaded wedge. **B.** The microtube is introduced so that its beveled end is oriented toward the outer wall of the canal in order to "scoop-up" the head of the broken file. **C.** The insert wedge is actively engaging and displacing the head of the file out the cutout window.

Fig. 32.41 **A.** The I.R.S. Instrument Removal System (Dentsply Maillefer). The kit contains two different gauged instruments used for grasping broken files. Each instrument is comprised of a microtube containing a beveled end and cutout window and an insert threaded

wedge. **B.** The microtube is introduced so that its beveled end is oriented toward the outer wall of the canal in order to "scoop-up" the head of the broken file. **C.** The insert wedge is actively engaging and displacing the head of the file out the cutout window.

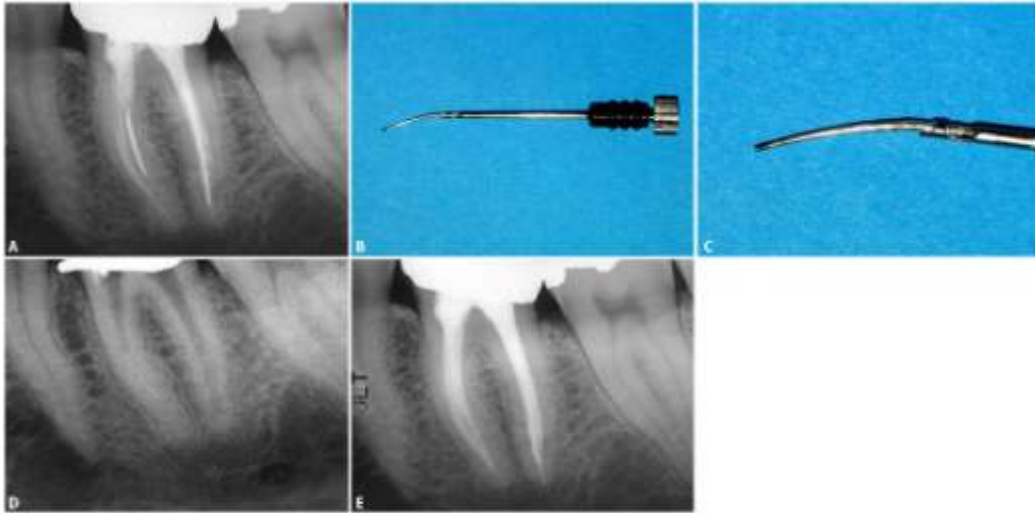


Fig. 32.42 **A**. This lower left first molar has two fragments of silver points, one in each root. **B, C**. With the I.R.S. the fragments of silver points are engaged and removed. **D**. The radiograph is confirming the complete removal of both fragments. **E**. Two year recall.

Repairing of perforations

Locating and repairing canal-periodontal ligament communications through a delicate and precise intra-canal access can only be accomplished with the aid of enhanced vision and illumination from a high powered microscope.²

In fact, the operating microscope will clearly demonstrate the location of perforations and allows for more efficient management of this complication (see Chapter 28).

Surgical Endodontics

Of all the areas in endodontics, surgical endodontics has perhaps benefited most by the introduction of the operating microscope. Although a comprehensive discussion of its role in surgical endodontics is beyond the scope of this chapter, the reader will gain some appreciation of the tremendous advance this instrument has provided by considering the following uses.

Surgical endodontics demands an entirely different set of skills than conventional endodontics. The practitioner must have a comprehensive knowledge and understanding of the multiple parameters involved in the management of both, hard and soft tissue, as well as an appreciation for the many factors involved in surgical wound healing. The operating microscope enhances surgical skill in both soft and hard tissue management. Light and visibility are critical for any

surgical procedure; the operating microscope provides levels of illumination and magnification that are appropriate for surgical endodontics.

Surgical correction of failing endodontic treatment has a checkered history. About 15 years ago some articles placed the success rate for apicoectomy at 40 to 60 percent.³⁰ The reason for such a low success rate were unknown and were the subject of much debate and speculation within the profession.³¹

Since there were undoubtedly a multitude of reasons for surgical failure, this chapter cannot address all these possibilities. Certainly one of the main causes of periapical breakdown following surgery is the failure to seal hermetically all portals of exit.³² This failure can be the result of inadequate lighting, visibility and technique. The following is a brief review of some of the errors commonly made in apical surgery and how the operating microscope can help to avoid such mistakes and raise the level of care.³

Soft tissue management

The most frequent errors in flap management in surgical endodontics is unnecessary trauma during incision, reflection, retraction and suturing. When sulcular incisions are made, frequently the sulcular epithelium is removed or crushed during the incision or elevation procedure. Preserving this tissue is probably the single most important factor in ensuring rapid wound healing.³³ The same principles should be applied when using the sub-marginal flap (Ochsenbein-Luebke). Microsurgical scalpel blades (Fig. 32.43), curved to conform to the cervical contour of

the tooth, enable the surgeon to make a sulcular incision without damaging the epithelial lining of the sulcus. When performed under the microscope, sharp dissection and completely atraumatic elevation of the papilla and interdental col area is accomplished. Specially designed currettes allow for an undermining elevation of the flap (Fig. 32.44). By elevating a full-thickness flap, maximum healing and reattachment potential are preserved. " When the flap is handled, under the microscope, the physical trauma is lessened and gentle manipulation is assured. Microsurgical suturing techniques take advantage of smaller gauge tapered-point needles and smaller suture sizes. Suture sizes of 5-0 and 6-0 are handled with ease (Fig. 32.45); sutures are placed much more accurately than with the naked eye. If one follows an atraumatic microsurgical flap management technique, sutures can be removed in 24 to 48 hours, with startling healing rates evident (Fig. 32.46).

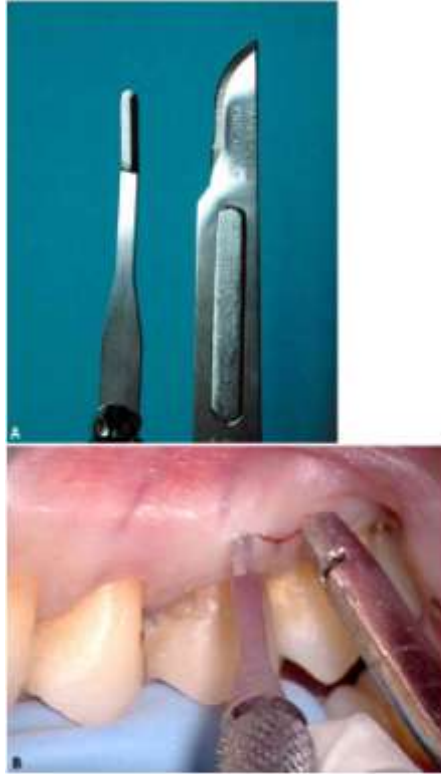

Fig. 32.43 **A.** Microsurgical scalpel (CX-2) compared with #15 blade. **B.** The microsurgical blade is making a sub-marginal flap.

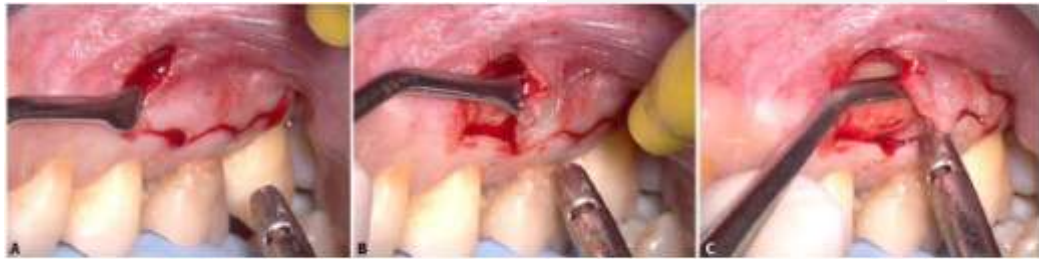

Fig. 32.44 **A-C.** Undermining flap elevation using Ruddle 30° Curette.

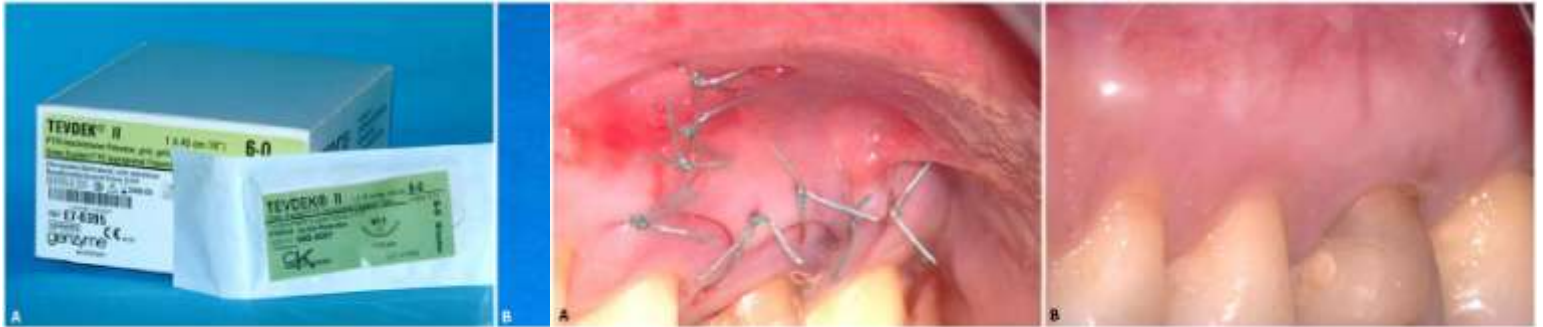

Fig. 32.45: A. Tevdek suture 6-0 is particularly indicated because it does not retain back. B. Immediate post-op suturing. C. The suture has been removed after 24 hours and this image shows a perfect healing with no scar after six months.

Root-End Procedures

Although the introduction of the operating microscope to endodontics is fairly recent, the surgical procedures that endodontists perform have always been true microsurgical procedures. Like other areas of endodontics, surgical endodontics is extremely technique-sensitive, with only a small margin for error. Traditionally, these procedures have been done without the lighting and magnification needed to perform them properly. Evaluation, preparation and filling of the root apex are true microsurgical procedures, and simply cannot be done predictably without magnification. Recently introduced optical grade micromirrors (Fig. 32.47) allow the surgeon to examine the beveled root apex in minute detail. The ability to observe the beveled edge of the root at high magnification brings a whole new world of detail into focus. Poorly condensed gutta-percha (Fig. 32.48), leakage around sealer voids, eccentric and irregular canal shapes (Fig. 32.49), uninstrumented isthmus areas

(Fig. 32.50), accessory canals (Fig. 32.51) and canal fins and circumferential resorption of prior retrofilling materials, all become very obvious, helping the practitioner design and implement a corrective design to his retro-preparation.

Based on a large number of microsurgical inspections of failed apicoectomies, these authors believe that one of the most significant problems in apical surgery responsible for such a high failure rate is poor design and preparation of the retro-preparation itself. Because instruments were not available to allow preparation down the long axis of the root, almost all retro-preparations were placed obliquely into the root (Fig. 32.52). This has the unfortunate consequence of having to rely on the axial wall of the preparation to do the sealing, when ideally it is the pulpal floor of the preparation which should do the sealing, with the axial walls only used for retention.

Because most roots sustain an exaggerated bevel at the time of their resection, the needed preparation must become broad buccal-lingually. This is exceedingly difficult to accomplish with conventional or microhandpiece preparations as one moves further lin-




Fig. 32.47. BE miniature retromirrors.

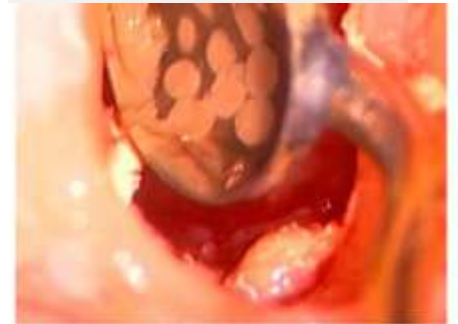

Fig. 32.48. View in retromirrors of a poorly condensed gutta-percha in a perforating internal resorption.

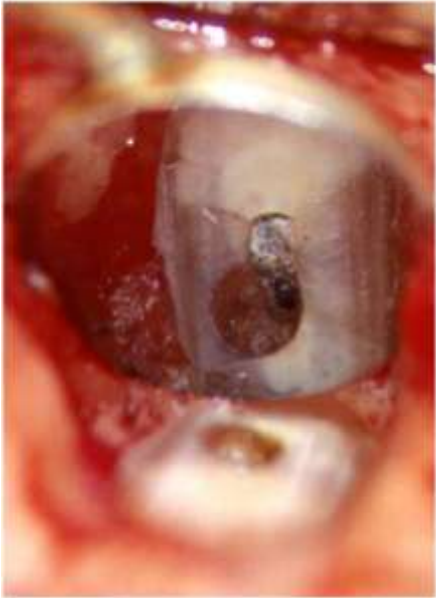
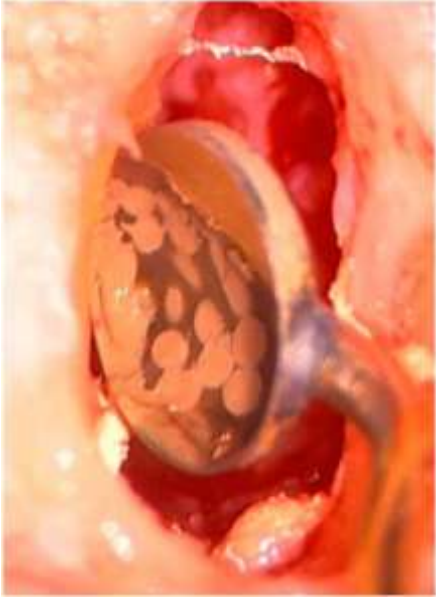
Fig. 32

49. Beveled edge of root with eccentric retro-prep made with a bur. The retrofi

I
l
i
n
g
m
a
t
e
r
i
a
l
h
a
s

j
u
s
t
b
e
e
n
r
e
m
o
v
e
d

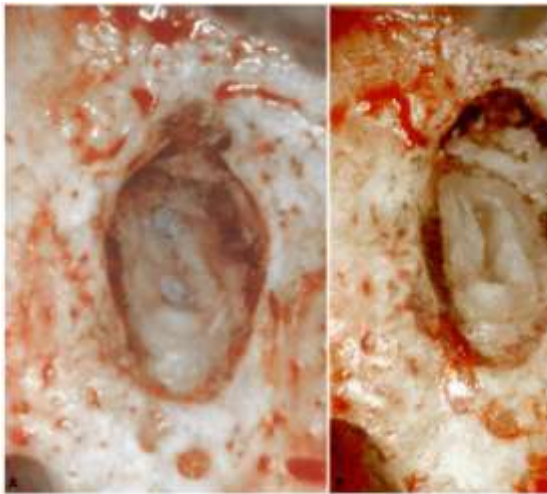

Fig. 32.50 **A**, Falling amalgam retrofill. The isthmus has not been included in the root canal. **B**, Retrofill with SuperEBA.

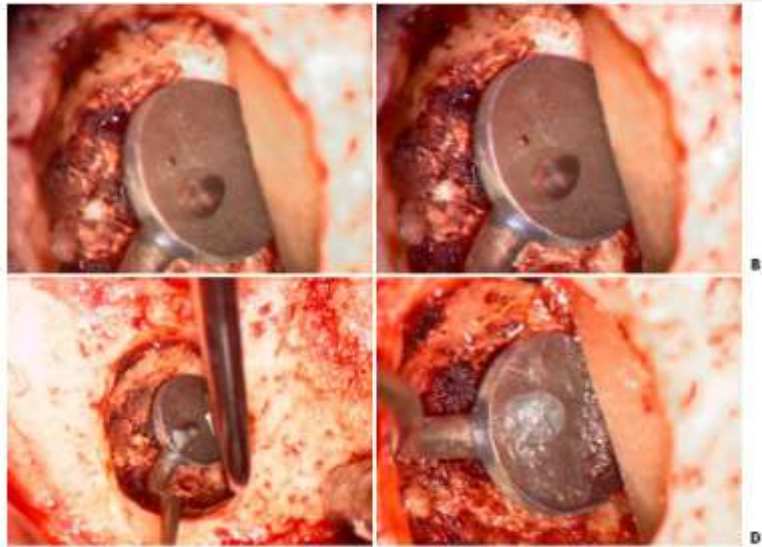


Fig. 32.51 **A**, Retro-mirror view of the orifice of a lateral canal. **B**, The micro-spatula is carrying the retrofilling material SuperEBA. **C**, Retro-mirror view of SuperEBA retrofill.

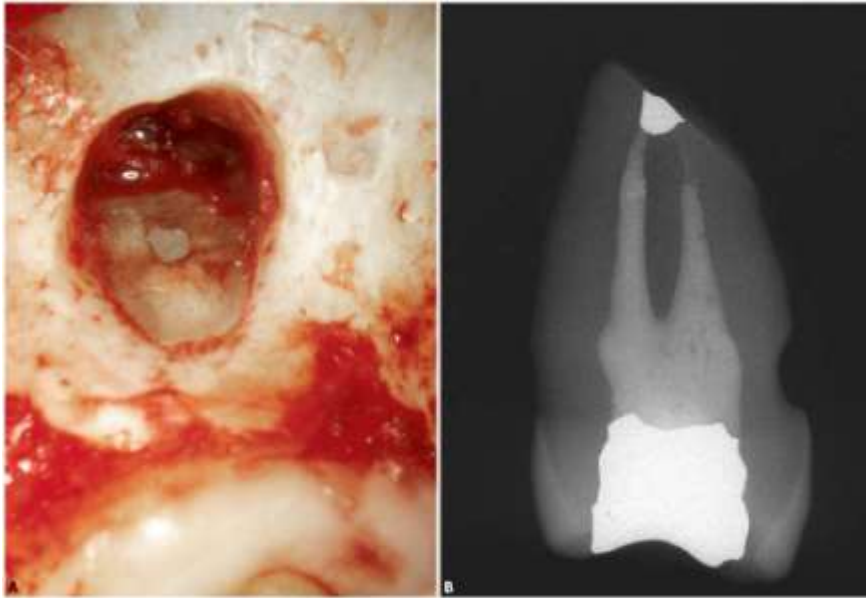


Fig. 32.52 **A**: Amalgam retrofill of an upper left second premolar. The root-end preparation has been made using a bur. **B**: 15 years later the tooth has been extracted because of a vertical root fracture. The radiograph shows the acute bevel, the root-end preparation inadequately extended buccal-lingually and not placed down the longitudinal axis of the pulpal space.

gually in the crypt.

Fortunately, the recent introduction of specialized ultrasonic tips solves this problem (Fig. 32.53). Now retropreparations can be placed down the longitudinal axis of the pulpal space and the preparations can be extended to the correct buccal-lingual dimension with ease. Using the surgical microscope and retromirrors, we can now modify the bevel and section roots more perpendicularly to the long axis of the root (Fig. 32.54). We also have the ability to inspect, prepare and seal the isthmus area between confluent canal systems (Fig. 32.55). This technique decreases the probability of lingual root perforations when the retropreparation must be extended lingually. Ultrasonic preparations are G. V. Black-type slot preparations with parallel walls, which conform to the anatomic reality of the root canal system. The ability to cut perpendicular to the long axis is especially helpful in cases where there is a post placed deep into the canal and where a standard bevel would expose the post and compromise the retrofilling procedure.

Together with the operating microscope, the surgeon can today use a complete series of micro-instruments,

specifically designed to work at high magnification.

The incision is made very precisely with the micro-scalpel CK 2, and the more precise incision allows a more accurate repositioning of the flap and a perfect healing with no scar tissue (Fig. 32.56).

The removal of the granulation tissue can be made more precisely and more completely, and this allows a better control of the bleeding in the bony crypt and less work relative to wound healing.

The cut or the root can be done with the high speed handpiece (Impact Air 45, Sybron Dental, Orange, Ca) (Fig. 32.57) perpendicular to the long axis, which allows less removal of root structure and lower number of exposed dentinal tubules. Because this turbine is offset at 45 degrees, the endodontic microsurgeon can also use this handpiece to gain better access to the apices of maxillary and mandibular molars. When used in conjunction with the operating microscope, a longshanked surgical bur can be placed with a high level of accuracy in the posterior regions of the mouth.

The use of ultrasonic retrotips allows retropreparations placed down the longitudinal axis of the root canal, completely cleaned 360° and easily ins

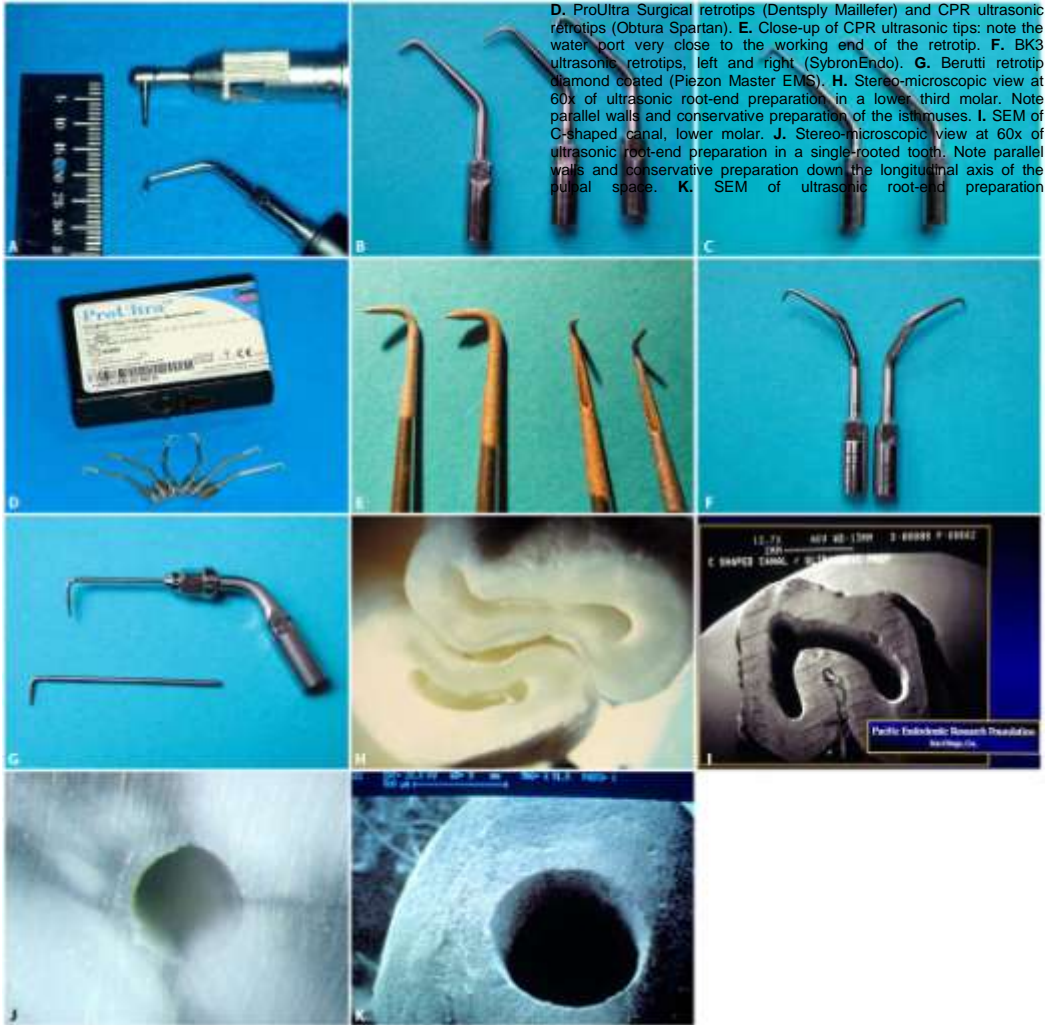

Fig 32.53. A. Note the small size of ultrasonic retrotip compared to a microhandpiece contra-angle. B. Set of EIE Ultrasonic Retrotips. C. EIE Ultrasonic Slim Jim tips.



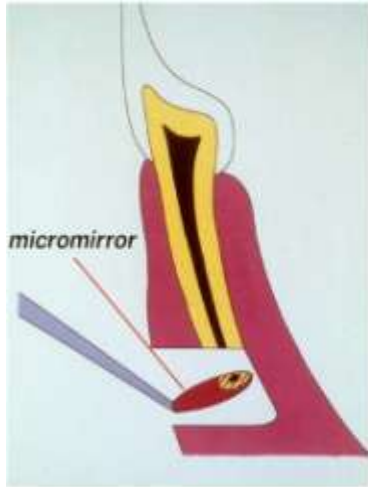


Fig. 32.54 Diagram

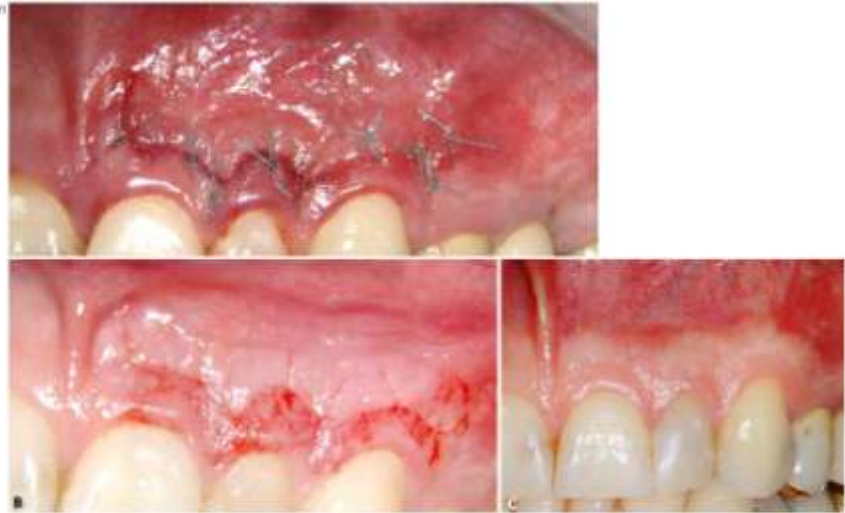

Fig. 32.56 **A**, Example of microsurgical suturing with Tevdek 6-0. **B**, Removal of suture after 24 hours. **C**, Six month recall showing lack of suture fracture.

Common Errors in Retropreparation

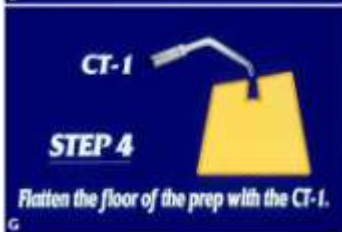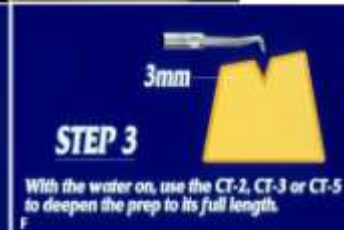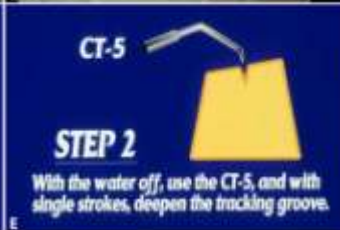


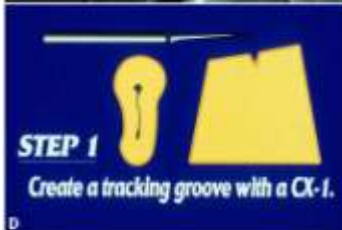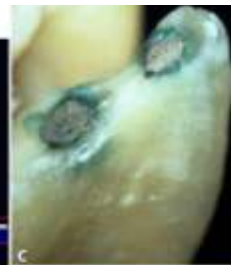Fig. 32.55. **A**, **B**, Seen view of uninstrumented isthmus. **C**, Extracted tooth of failed apico with amalgam retrofill; the isthmus has not been included in the root-end preparation. **D-G**, Diagrammatic view of the four steps of the preparation of isthmus.



Fig. 32.57: Impact Air handpiece with a Lindemann Bone Cutting Bur.

pecte
d
with
micr
omirr
ors

befor
e
retro
fill.

The beveled surface can be easily examined for the presence of apical vertical root fractures (Fig. 32.58), lateral canals, isthmuses. In recent studies,^{18,25} a complete or partial isthmus was found at the 4mm level of the mesiobuccal root of the maxillary first molar 100% of the time, and a complete isthmus was found 90% of the time at the 3mm level of the mesial root of the mandibular first molar.

When present, the isthmus can be accurately prepared and sealed, without any risk of weakening the root structure. (Fig. 32.59)

The use of micromirrors enables the clinician to look up into the apical preparation to check for completeness of tissue removal (Fig. 32.60). Before using these mirrors, it was impossible to assess the thoroughness of apical preparation. Failure to completely remove old root canal filling material and debris from the facial wall of the apical preparation before placement of an apical seal may be why many surgeries failed in the past.¹⁷

Lateral canals can be easily visualized, located and filled, in order to accomplish a three-dimensional cleaning, shaping, and obturation of the root canal system through a surgical approach.

Suturing can also be accomplished more precisely using the operating microscope (even though some author¹⁹ thinks that suturing doesn't need ma

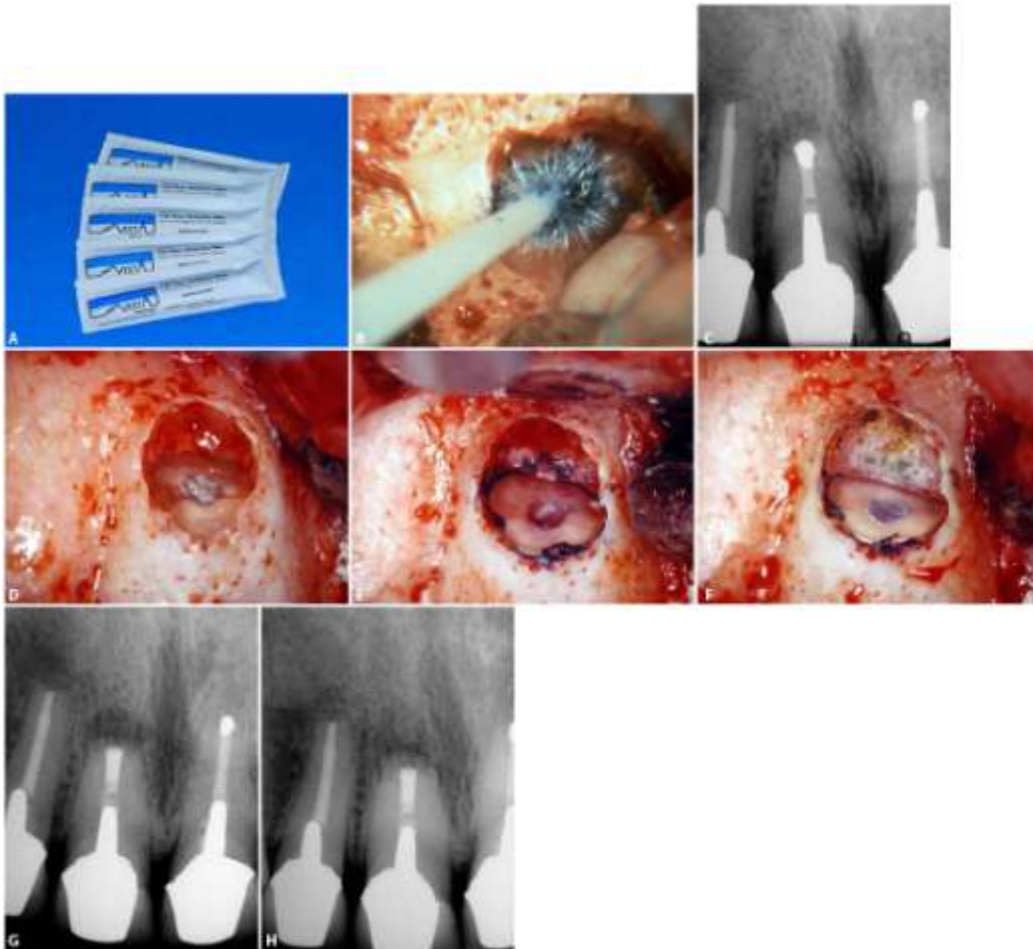


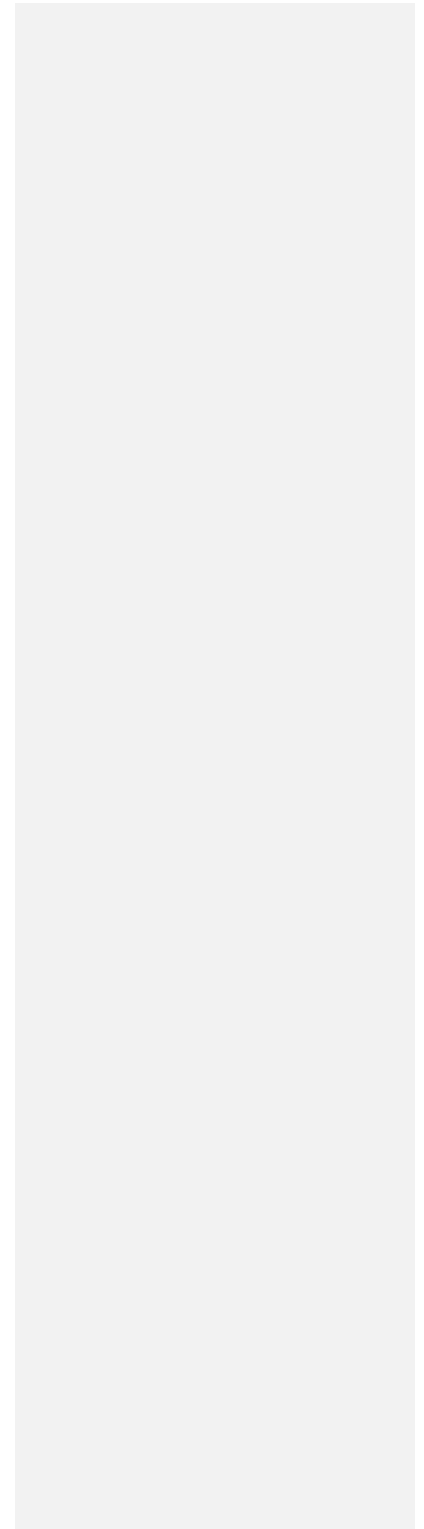
Fig. 32.58. **A.** Unit dose Methylene Blue by Vista Dental, Racine, WI, USA. **B.** Application of Methylene blue in a clinical case. **C.** Pre-operative radiograph of the upper right central incisor. **D.** Clinical view before application of Methylene blue. An apical vertical root fracture is evident in a medio-distal direction. **E.** Clinical view after the removal of one or two millimeters of root and the application of Methylene blue; the fracture has been completely removed. **F.** Clinical view of final re-otilling.

G. Post-operative radiograph. **H.** Three year recall.

gnification), allowing a more rapid healing by primary A recent prospective study¹⁸ showed that the sucintention and an early removal of the suture itself. cess rate of surgical endodontics performed

under the

- The removal of the suture, if made with ma-operating microscope with microsurgical technique gnification, will be easier, with no bleeding and no di-was 96.8%. The average healing rate independent of scomfort for the patient (Fig. 32.61). lesion size was 7.2 months.



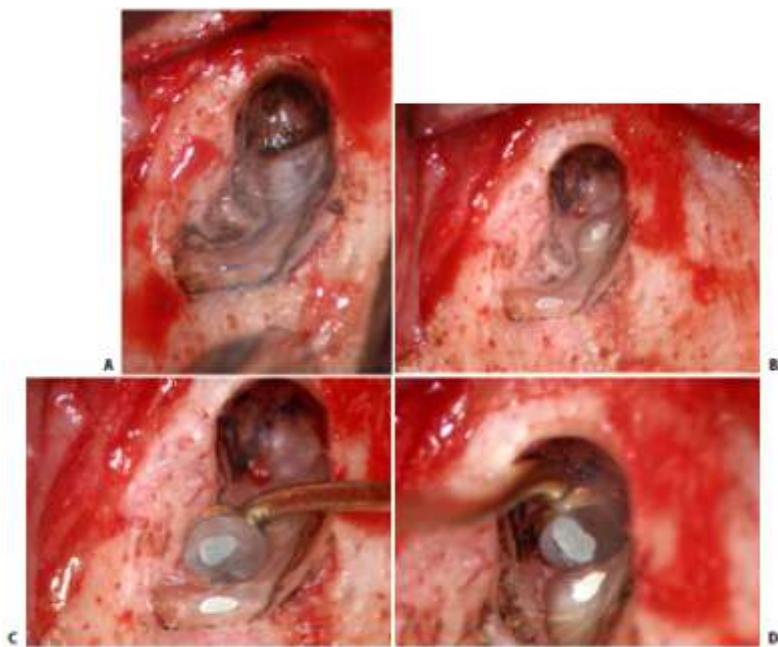


Fig. 32.59. **A.** In this mesio Buccal root of an upper first molar the application of Methylene blue did not evidentiate the isthmus, therefore both root-end preparations were made separately. **B.** Clinical view of final retrofilling. **C.** Clinical showing hi-mag retrointraoral view of final retrofilling of MB1. **D.** Clinical showing hi-mag retrointraoral view of final retrofilling of MB2.

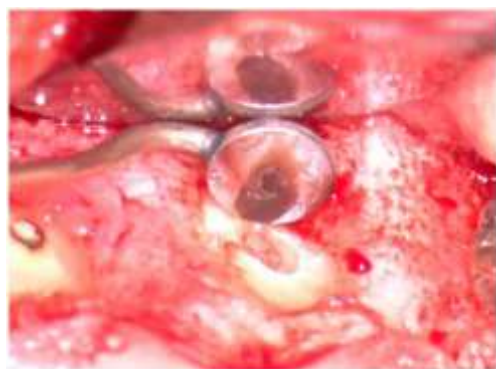

Fig. 32.60. Retrointraoral view of ultrasonic root-end preparation.

Learning curve

As stated above, introducing an operating microscope into a dental office involves a sophisticated understanding of the role and importance of ergonomic practice. There is a learning curve in becoming competent at working at high magnification and performing most procedures indirectly, using a smaller mirror. The more the microscope is used, the shorter the learning curve will be. Sporadic or intermittent use, on the other hand, frequently leads to only frustration. Furthermore, since working under the microscope involves working with “four hands,” it becomes mandatory to motivate and train the dental assistant.

Competency in microscope use can be acquired very quickly with a disciplined and professional approach to training. Rarely does one struggle for more than a month or two if a conscientious effort is made.

A

Fig. 32.61. **A.** The microsurgical blade is making a sub-marginal flap. **B.**

Conclusion

The operating microscope has revolutionized the specialty of endodontics. It represents a quantum leap in the development of competence for endodontics and dentistry in general. The increased magnification and the coaxial illumination have enhanced the treatment possibilities in non-surgical and surgical endodontics.

Treatment modalities that were not possible in the past have become reliable and predictable.

We can state that microscopes in endodontics represent what the discovery of X-ray radiations represented for dentistry more than 100 years ago. As today we cannot imagine a dental office without the X-ray machine, in the same way we can state that the day is not far away when dentistry will be entirely and diffusely performed under the operating microscope. All endodontic graduate programs are now teaching its use as part of their curriculum. The only limitation that exist for the operating microscope is the

BIBLIOGRAPHY

- 1 . APOTHEKER, H.: A microscope for use in dentistry. J. Microsurg. 3:7, 1981.
2. ARENS, D.E.: Introduction to magnification in endodontics. J.

C D

Micro-scissor. **C.** The removal of the suture is made after 24 hours under the microscope. **D.** Complete healing after one month, with no scar formation.

imagination and it is certainly a most useful adjunct in the continual search for endodontic excellence.¹⁶

The future

The next stage in microscopic endodontics will involve the use of even finer microscopic instruments and the development of even more sophisticated techniques. Eventually, endodontists will be able to re-vascularize the pulp and grow dentin. These procedures will most certainly be microscopic in nature and will be quickly embraced by a specialty already well trained in microscopic procedures.

In the meantime, microscopic procedures are being adopted by the other specialties in dentistry with impressive results. Restorative dentists and periodontists will be the next disciples to embrace a microscopic approach, and then it will be only a matter of time before all of operative dentistry is performed microscopically.³

Esthet. Restor. Dent. 15:426, 2003.

- 3 . CARR, G.B.: Microscopes in endodontics. J. Calif. Dent. Assoc. 20(11):55, 1992.
- 4 . CARR, G.B.: Advanced techniques and visual enhancement for endodontic surgery. Endo. Report, 7:6, 1992.
- 5 . CARR, G.B.: Magnification and illumination in endodontics. In: Hardin FJ, ed. Clark's Clinical Dentistry, St. Louis, MO, Mosby; Vol. 4, 1-14, 1998.

- 1 CARR, G.B.: Controlling physical stress in microscopic dentistry. *Global Insights*, 5(1):1, 1999.
- 2 CASTELLUCCI, A.: Avancées technologiques en chirurgie endodontique. *Realites Cliniques*, 12(1):213, 2001.
- 3 CASTELLUCCI, A.: Magnification in endodontics: the use of the operating microscope. *Pract. Periodont. Aesthet. Dent.* 15(5):377, 2003.
- 4 FRANK, A., GLICK, D., et al: Long-term evaluation of surgically placed amalgam fillings. *J. Endod.* 18:391, 1992.
- 5 FRIEDMAN, S., LÜSTMANN, J., SHAHARDANY, V.: Treatment results of apical surgery in premolar and molar teeth. *J. Endod.* 17:30, 1991.
- 6 GUTTMAN, J., HARRISON, J.: *Surgical Endodontics*. Boston: Blackwell Scientific Publications, Inc., 313-16, 1991.
12. KHAYAT, B.G.: The use of magnification in endodontic therapy: the operating microscope. *Pract. Periodont. Aesthet. Dent.* 10(1):137, 1998.
13. KULID, J.C., PETERS, D.D.: Incidence and configuration of canal systems in the mesiobuccal root of maxillary first and second molars. *J. Endod.* 16:311, 1990.
14. MICHAELIDES, P.L.: Use of the operating microscope in dentistry. *J. Calif. Dent. Assoc.* 24(6): 45, 1996.
15. MOUNCE, R.: Surgical operating microscopes in endodontics: the quantum leap. *Dentistry Today*, 12(8):79, 1993.
16. NAHMIAS, Y.: Microscopic endodontics. *Oral Health*, May:31, 1997.
17. RUBINSTEIN, R.: Endodontic microsurgery and the surgical operating microscope. *Compendium*, 18(7): 659, 1997.
18. RUBINSTEIN, R., KIM, S.: Results of 94 endodontic microsurgies using SuperEBA retrofill. *J. Endod.* 22:188, 1996.
19. RUBINSTEIN, R.: The anatomy of the surgical operating microscope and operating positions. *Dent. Clin. North Am.* 41(3): 391, 1997.
20. SELDEN, H.S.: The dental-operating microscope and its slow acceptance. *J. Endod.* 28:206, 2002.
21. SHEETS, C.G., PAQUETTE, J.M.: The magic of magnification. *Dentistry Today*, 17(12):84, 1998.
22. SOMMER, R.F.: Essentials for successful root resection. *Am. J. Ortho. Oral Surg.* 32:76, 1946.
- 1 STRASSLER, H.E.: Enhanced visualization during dental practice using magnification systems. *Compendium*, 19(6): 595, 1998.
- 2 STROPKO, J.J.: Canal morphology of maxillary molars: Clinical observations of canal configurations. *J. Endod.* 25:446, 1999.
25. WELLER, N., NIEMCZYK, S., KIM, S.: The incidence and position of the canal isthmus: part 1. The mesiobuccal root of the maxillary first molar. *J. Endod.* 21:380, 1995.